FMC HGE

Les journées DE FORMATION 25ème édition CONTINUE

Laurent SIPROUDHIS
P COULOM

Intérêt des explorations complémentaires dans les troubles de la statique pelvienne

- - Connaitre les explorations complémentaires dans les troubles de la statique
- - Connaitre celles qui sont utiles

Troubles de la statique pelvienne

Pertinence des explorations fonctionnelles

Lyon FMC HGE 18 mars 2007

Pertinentes explorations…

- Exploration radiologique dynamique
  - IRM dynamique
  - Echographie
  - Défécographie
- Exploration fonctionnelle anorectale
  - Manométrie anorectale avec compliance
- Étude fonctionnelle colique
  - Calendrier des selles
  - Temps de transit colique

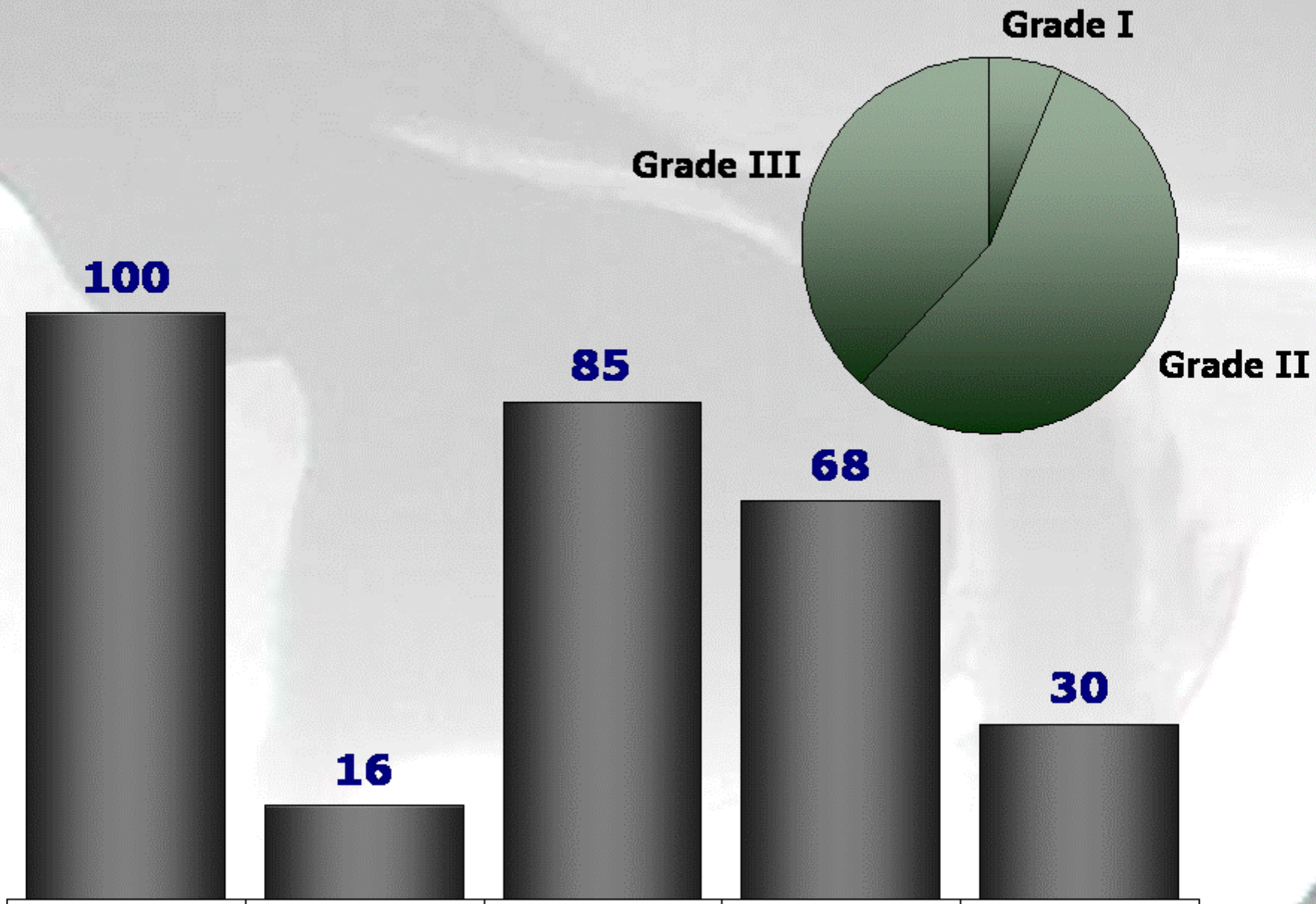
Grade I
Grade III
Grade II
100
16
85
68
30

Qu’attendre des examens?

- *Quantifier objectivement le handicap*
- *Rechercher des associations fonctionnelles*
- *Identifier les éléments de moins bon pronostic*
- *Choisir les thérapeutiques les plus adaptées*

Diseases of the Colon & Rectum

Long-Term Rectocele

Horace Roman

Int Urogynecol J (2003) 14: 160–163
DOI 10.1007/s00192-002-1019-y

ORIGINAL ARTICLE

defects

Diseases of the Colon & Rectum

Int J Colorectal Dis (2003) 18:342–348
DOI 10.1007/s00384-002-0469-5

and Anatomic Outcom
Rectocele Repair U
A Prospective S

ORIGINAL ARTICLE

C.E.J. Sloots
A.J. Meulen
R.J.F. Felt-Bersma

L. Burrows · Catherine Sewell
S. Leffler · Geoffrey W. Cundiff

acy of clinical evaluation of posterior vaginal wall

ansanal

Charles Nicolle

Rectocele repair improves eva
and prolapse complaints indepe
of anorectal function and colonic

Original article

Does the need to self-digitate or the presence of a large or nonemptying rectocoele on proctography influence the outcome of transanal rectocoele repair?

S. G. Stojkovic, L. Balfour, D. Burke, P. J. Finan and P. M. Sagar

The General Infirmary at Leeds, Leeds, UK

Original article

Diseases of the Colon & Rectum

nctional and physiologic
of rectocele

and D. Kumar

Diseases of the Colon & Rectum

Laparoscopic or Transanal Repair
Rectocele? A Retrospective Matched
Cohort Study

M. J. Thornton, F.R.A.C.S., L.L.B.,[1] A. Lam, F.R.A.N.Z.C.O.G.,[2] D. W. King, F.R.A.

[1] Department of Colorectal Surgery, St. George Hospital, Sydney, Australia
[2] Department of Gynaecology and Obstetrics, St. George Hospital, Sydney, Australia

Transanal or Vaginal Approach to Rectocele Repair: A Prospective, Randomized Pilot Study

Kari Nieminen, M.D.,[1,2] Kari-Matti Hiltunen, M.D.,[3] Jukka Laitinen, M.D.,[4] Juha Oksala, M.D.,[5] Pentti K. Heinonen, M.D.[1,2]

Qu’attendre des examens?

- Quantifier objectivement le defect et le handicap
- Rechercher des associations fonctionnelles
- Identifier les éléments de moins bon pronostic
- Choisir les thérapeutiques les plus adaptées

Int Urogynecol J (2006) 17: 615–620
DOI 10.1007/s00192-006-0076-z

ORIGINAL ARTICLE

Steven Swift · Sarah Morris · Vikki McKinnie ·
Robert Freeman · Eckhard Petri ·
Richard J. Scotti · Peter Dwyer

Validation of a simplified technique for using the POPQ pelvic organ prolapse classification system

Table 1 Inter-examiner reliability for the simplified pelvic organ prolapse classification system: overall stage

Exam 1	Exam 2			
	Stage 1	Stage 2	Stage 3	Stage 4
Stage 1	17	2	0	0
Stage 2	2	14	0	0
Stage 3	0	1	10	1
Stage 4	0	0	0	1

Kappa statistic .86

Int Urogynecol J (2005) 16: 96–103
DOI 10.1007/s00192-004-1220-2

ORIGINAL ARTICLE

Daniel Altman · Annika López · Jonas Kierkegaard
Jan Zetterström · Christian Falconer · Johan Pollack
Anders Mellgren

Assessment of posterior vaginal wall prolapse: comparison of physical findings to cystodefecoperitoneography

Patient	POP-Q point Bp (cm)	POP-Q point C/D (cm)	POP-Q stage posterior vaginal wall	Posterior vaginal wall prolapse at CDP	Other findings at CDP
1	–2	–3	I	0	RI
2	–2	–1	I	0	0
3	–2	–10	I	0	RP
4	–2	–9	I	0	0
5	–2	–9	I	Rc 2 cm	RI
6	–2	–5	I	Rc 4 cm, Ec 4.5 cm	RI
7	0	–10	II	Pc 3 cm	RI
8	+1	–8	II	Rc 4 cm, Pc 5 cm	0
9	+1	+3	II	Ec 5 cm	RI
10	+1	–10	II	Rc 4 cm	0
11	+1	–8	II	Rc 4.5 cm	0
12	–1	–4	II	Rc 4 cm	RI
13	0	–10	II	Rc 5 cm	0
14	0	–2	II	Rc 4 cm, Ec 2.5 cm	RI
15	+1	–7	II	Rc 4 cm, Pc 3 cm	RI
16	–1	–9	II	Rc 4 cm, Ec 7 cm	RI
17	–1	–2	II	Ec 4.5 cm	RI
18	0	+3	II	Ec 6 cm	0
19	+1	–8	II	Rc 3 cm, Ec 2.5 cm	0
20	–1	–9	II	Rc 3 cm, Pc 10 cm	RI
21	0	–9	II	Rc 4 cm	RI
22	–1	–2	II	Rc 2 cm	RI
23	+1	–4	II	Rc 3 cm, Ec 3 cm	0
24	–1	–9	II	Rc 3 cm, Pc 2.5 cm	RI
25	0	–10	II	Rc 4 cm, Pc 5 cm	RI
26	+1	+1	II	Rc 3.5 cm	RI
27	0	–6	II	Pc 8 cm	0
28	–1	–4	II	Rc 4 cm, Pc 3 cm	RI
29	+1	–10	II	Rc 6 cm, Ec 5 cm	RI
30	0	–9	II	Rc 3 cm	RI
31	0	–3	II	Rc 4 cm, Ec 5 cm	0
32	0	–9	II	Ec 6 cm	RI
33	+1	–8	II	Rc 4 cm, Ec 8 cm	RI
34	+3	–7	III	Rc 4 cm, Ec 5 cm	RP
35	+2	–6	III	Rc 4 cm	RI
36	–1	+3	III	Pc 5 cm	0
37	+3	–9	III	Rc 6.5 cm	0
38	+3	–9	III	Rc 5 cm, Ec 10 cm	RI

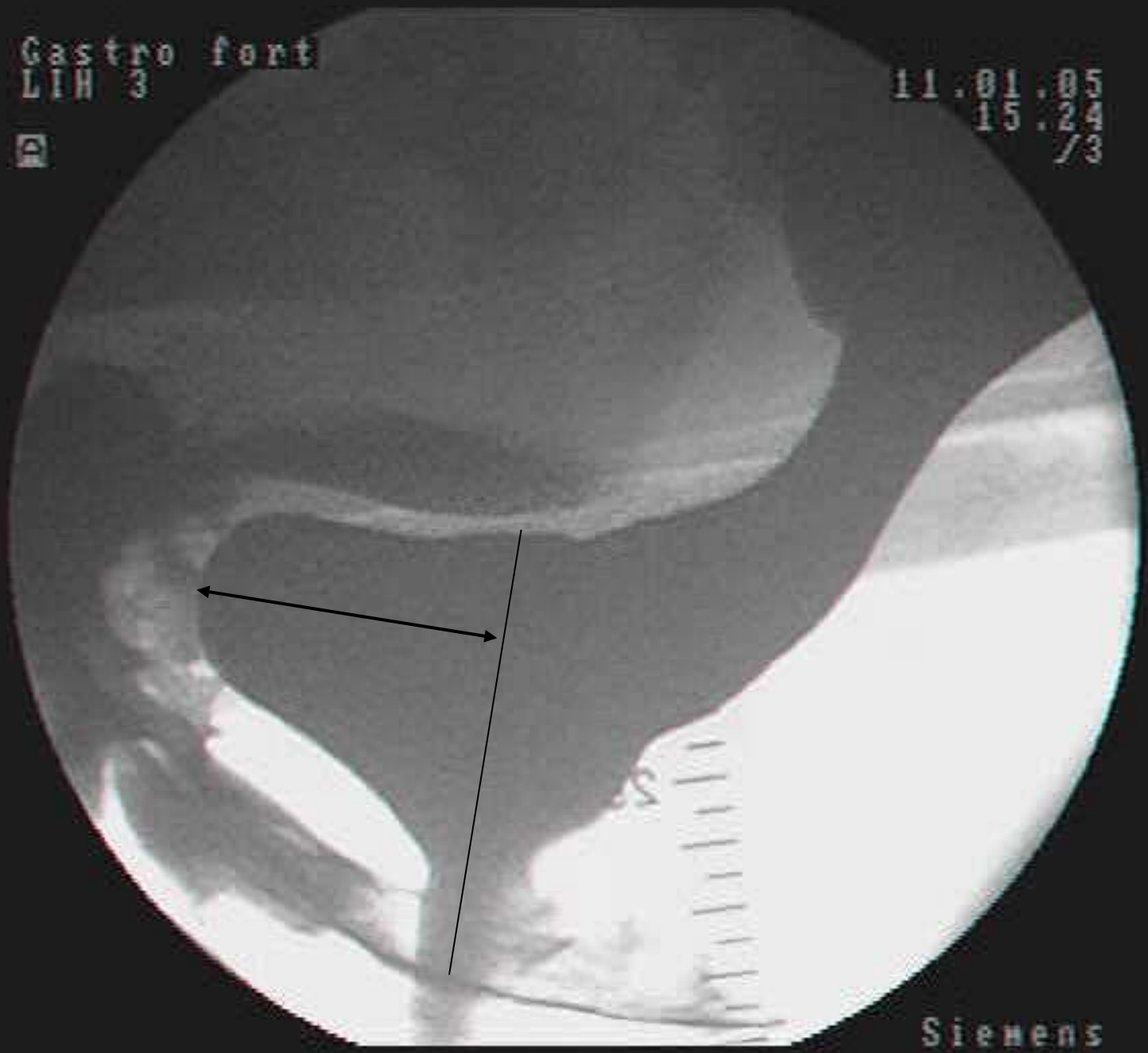
Gastro fort
LIH 3
11.01.05
15.24
/3
Siemens

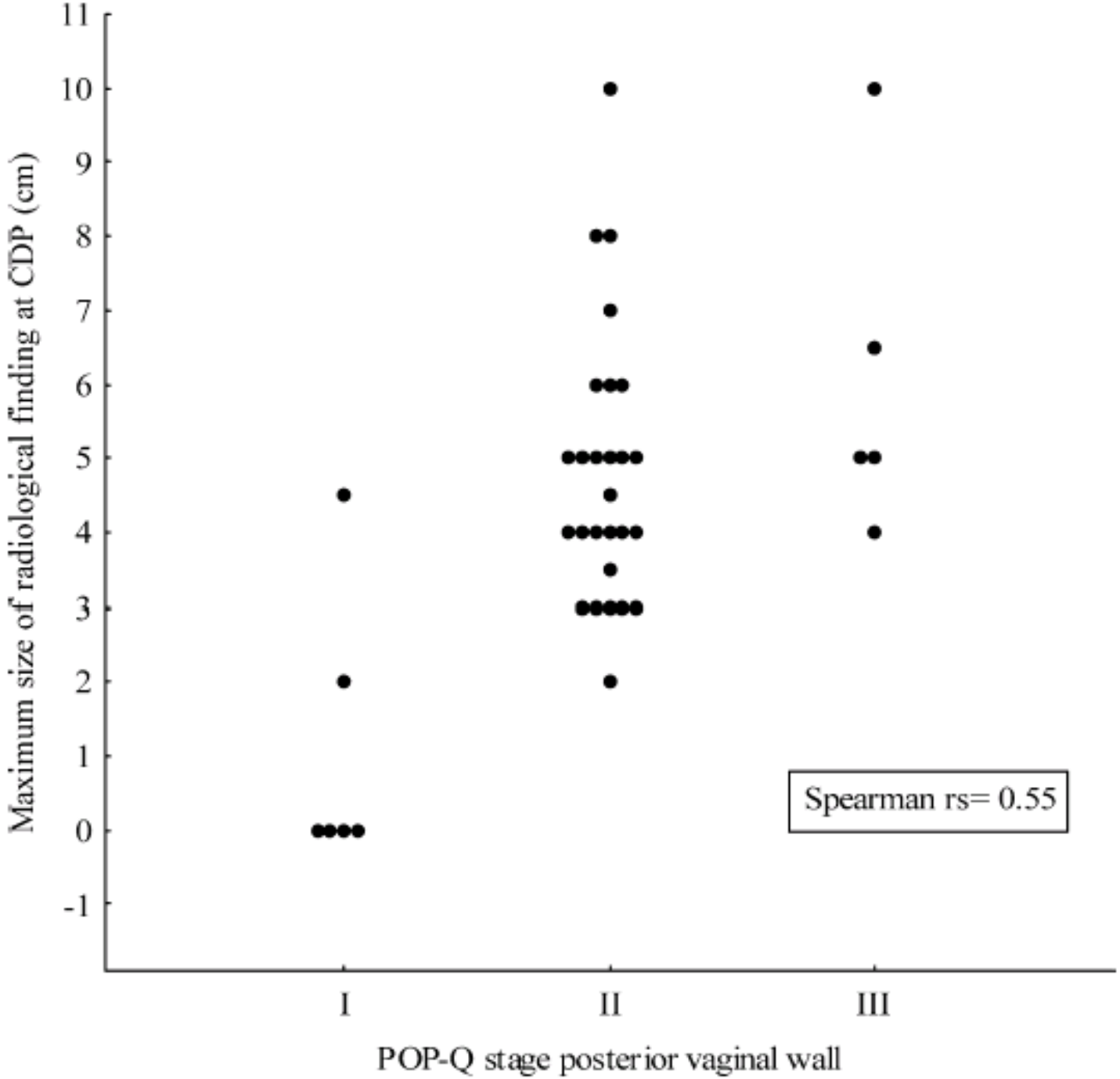
Maximum size of radiological finding at CDP (cm)
11
10
9
8
7
6
5
4
3
2
1
0
-1
Spearman rs= 0.55
I
II
III
POP-Q stage posterior vaginal wall

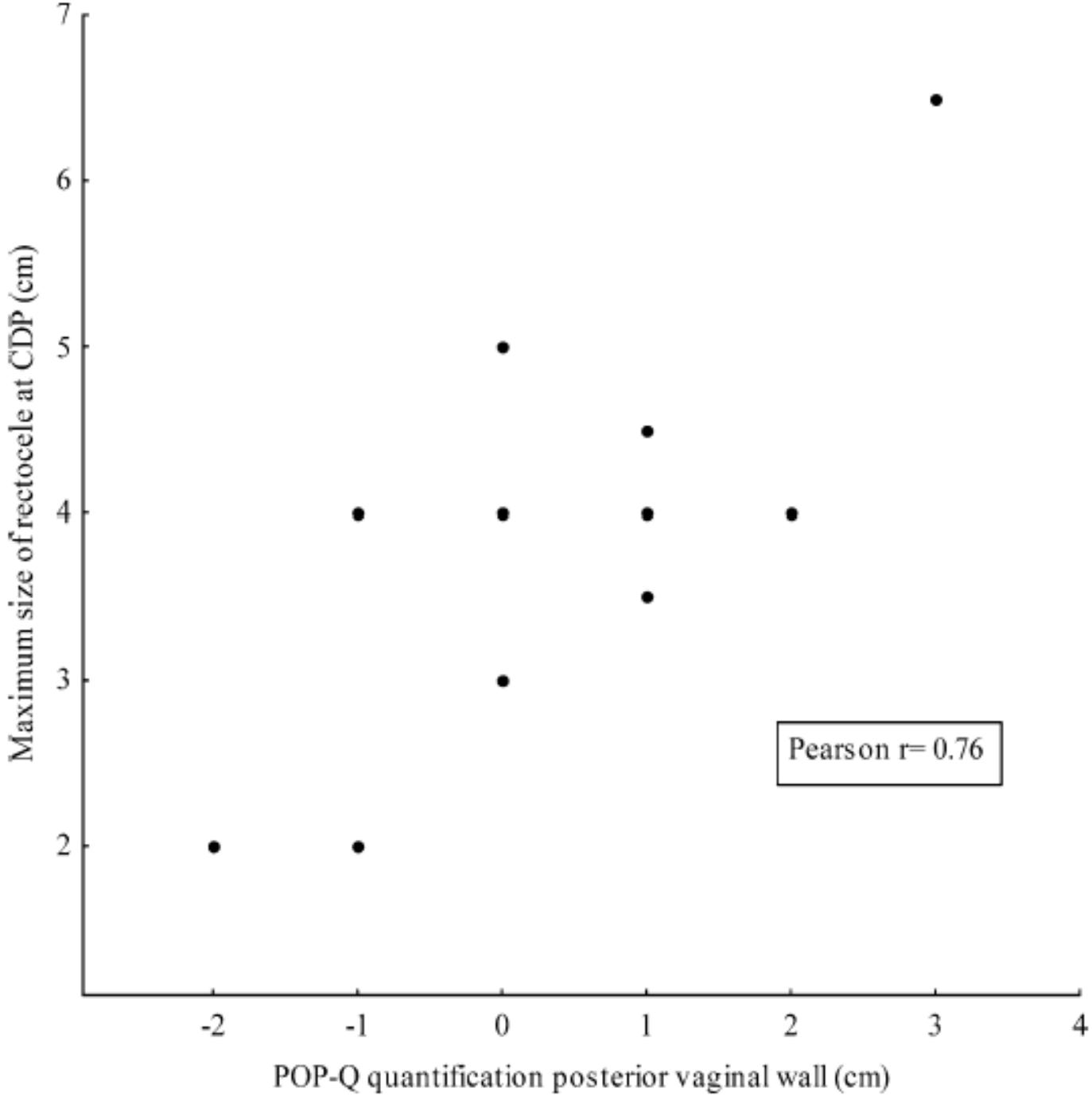
Maximum size of rectocele at CDP (cm)
7
6
5
4
3
2
-2
-1
0
1
2
3
4
POP-Q quantification posterior vaginal wall (cm)
Pearson r= 0.76

Original article

Functional and physiological outcome following transanal repair of rectocele

A. G. Heriot, A. Skull and D. Kumar

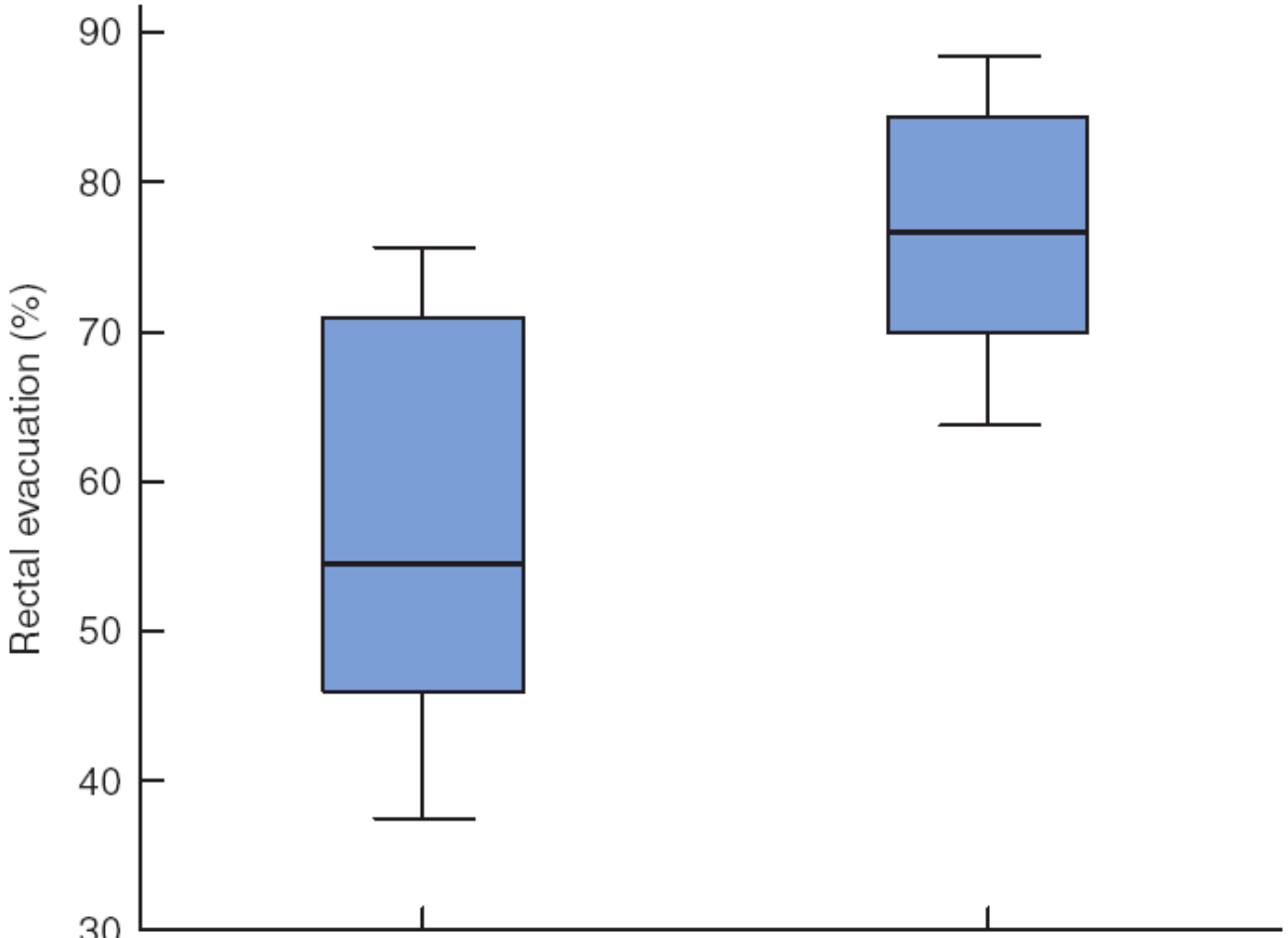


Gastro fort
LIH 3
11.01.05
15.23
/3
Siemens

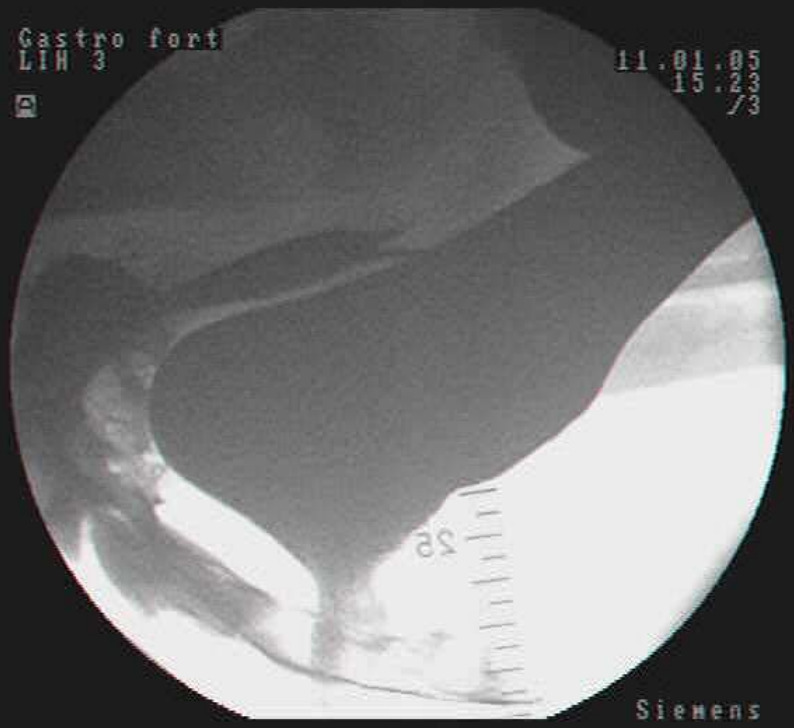
Gastro fort
LIH 3
11.01.05
15.23
/3
Siemens

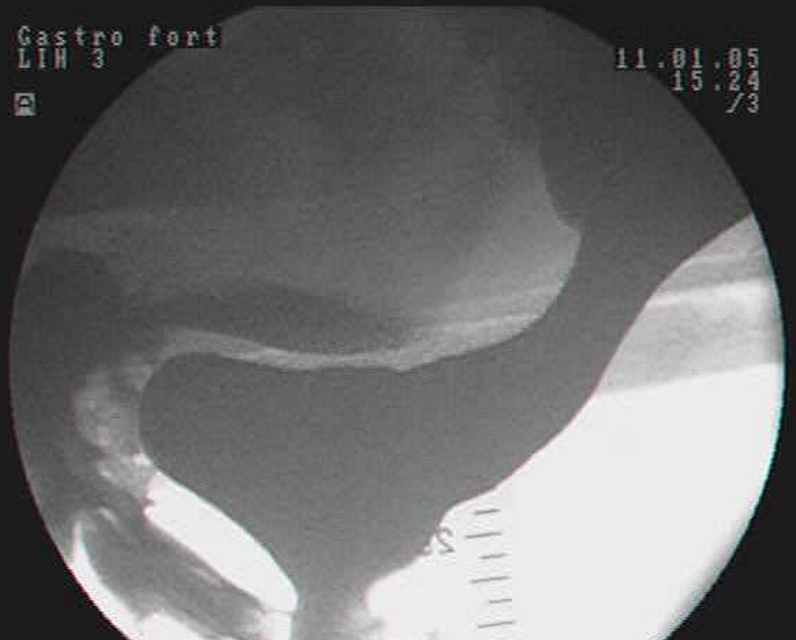
Gastro fort
LIH 3
11.01.05
15.24
/3

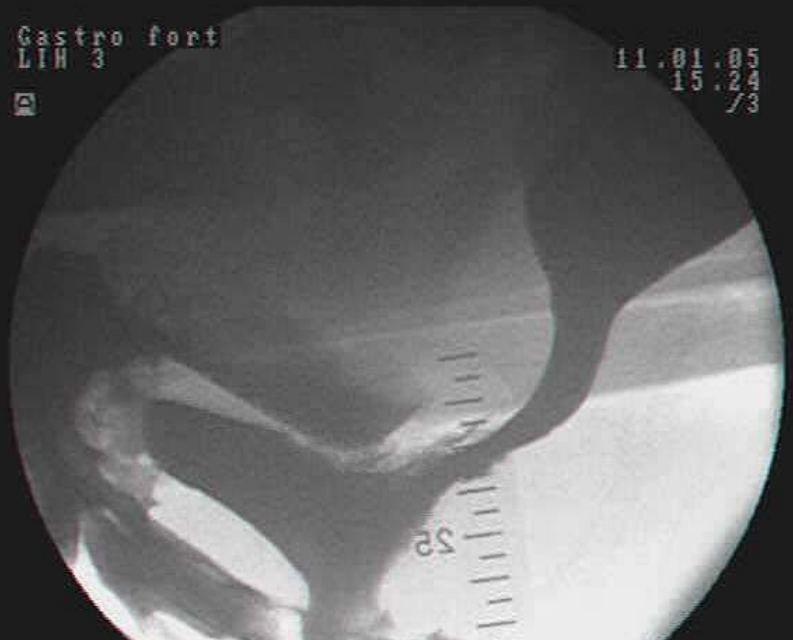
Gastro fort
LIH 3
11.01.05
15.24
/3

ELSEVIER

VALUE OF EXPRESS T_2-WEIGHTED PELVIC MRI IN THE PREOPERATIVE EVALUATION OF SEVERE PELVIC FLOOR PROLAPSE: A PROSPECTIVE STUDY

ROBERT R. KESTER, LINE LEBOEUF, MARCO A. AMENDOLA, SANDY S. KIM, ALDERE BENOIT, AND ANGELO E. GOUSSE

findings. A significant correlation was found between the preoperative pelvic examination and operative findings for cystocele ($r = 0.61$, $P = 0.005$) and vaginal cuff prolapse ($r = 0.75$, $P = 0.008$). The preoperative pelvic examination did not correlate with the operative findings of uterine prolapse, enterocele, or rectocele. On the other hand, the comparison of the MRI and operative findings showed a significant correlation in all types of pro-

Int Urogynecol J (2003) 14: 160–163
DOI 10.1007/s00192-002-1019-y

ORIGINAL ARTICLE

Lara J. Burrows · Catherine Sewell
Kenneth S. Leffler · Geoffrey W. Cundiff

The accuracy of clinical evaluation of posterior vaginal wall defects




VPP
52
70
24
54
inférieure
supérieure
médiane
gauche

Australian and New Zealand Journal of Obstetrics and Gynaecology 2005; 45: 505–508

Original Article

Which bowel symptoms are most strongly associated with a true rectocele?

Hans Peter DIETZ[1] and Andrew KORDA[2]

[1]*University of Sydney, Penrith, and* [2]*Royal Prince Alfred Hospital, Sydney, Australia*

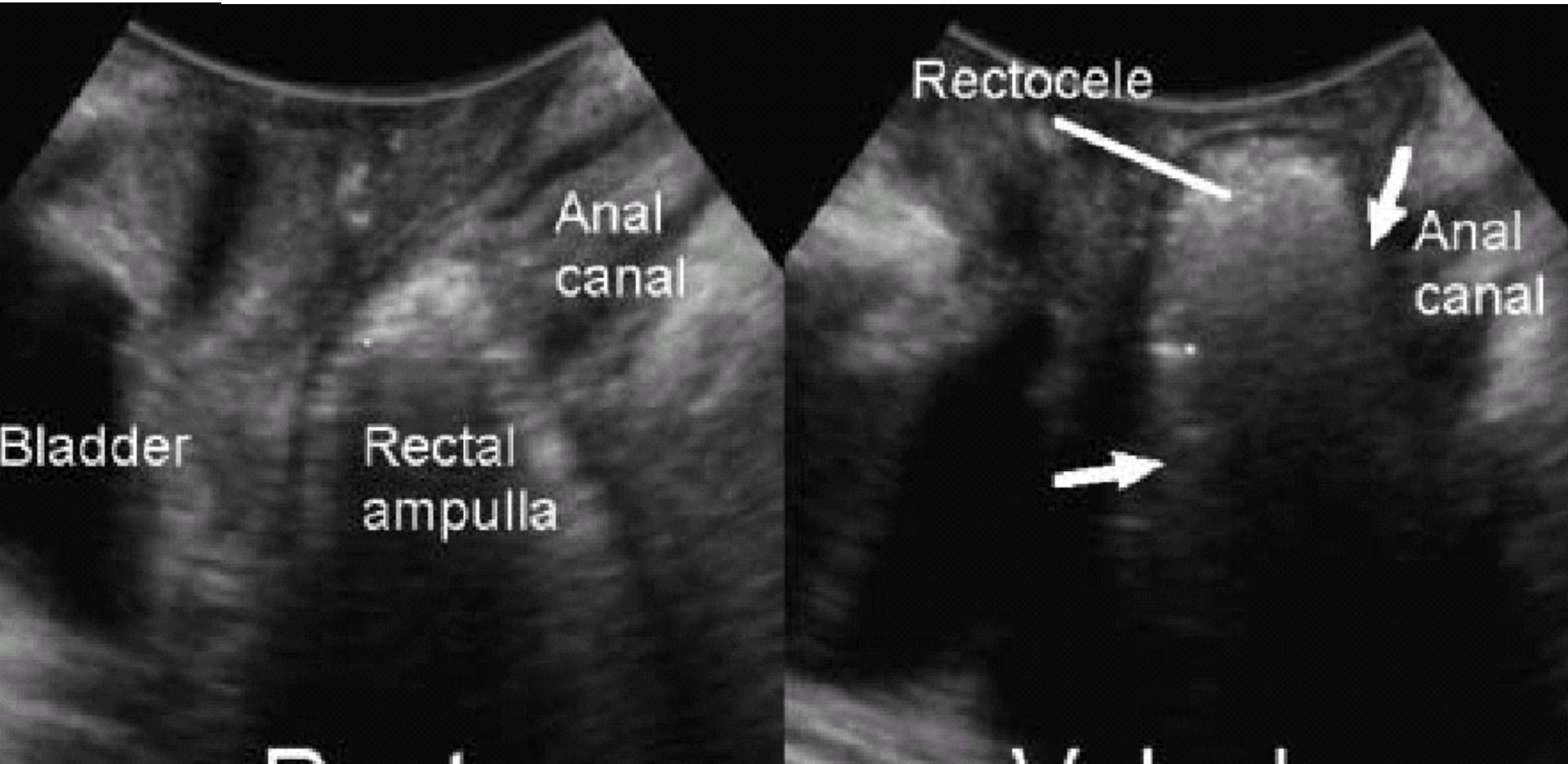

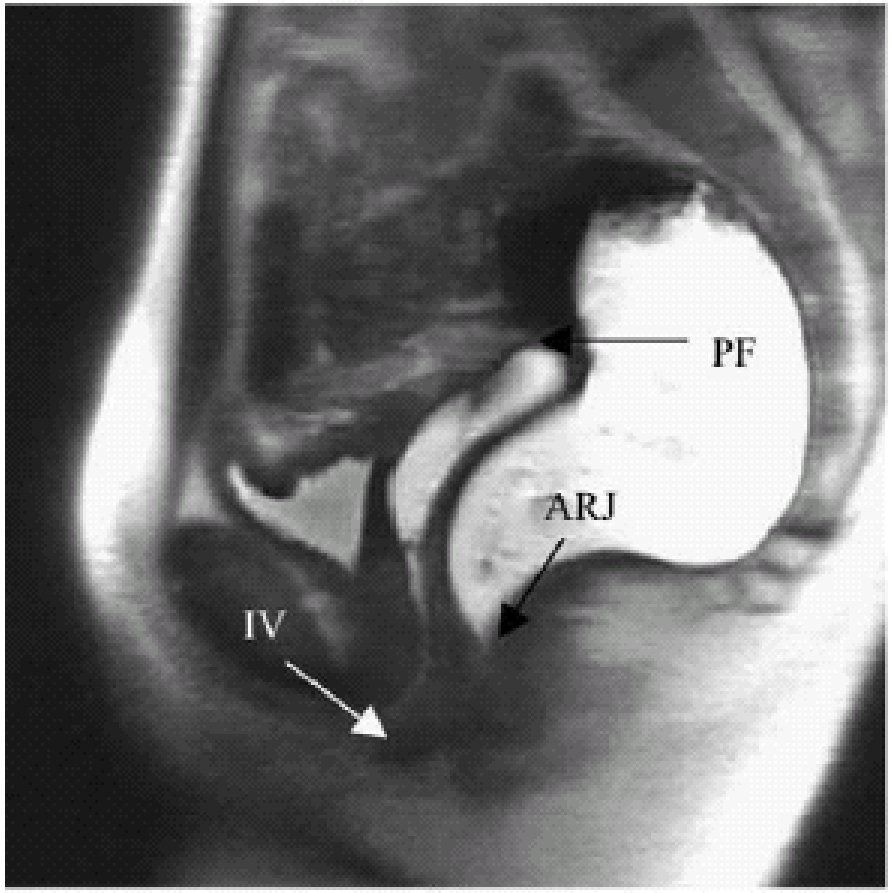

(c)

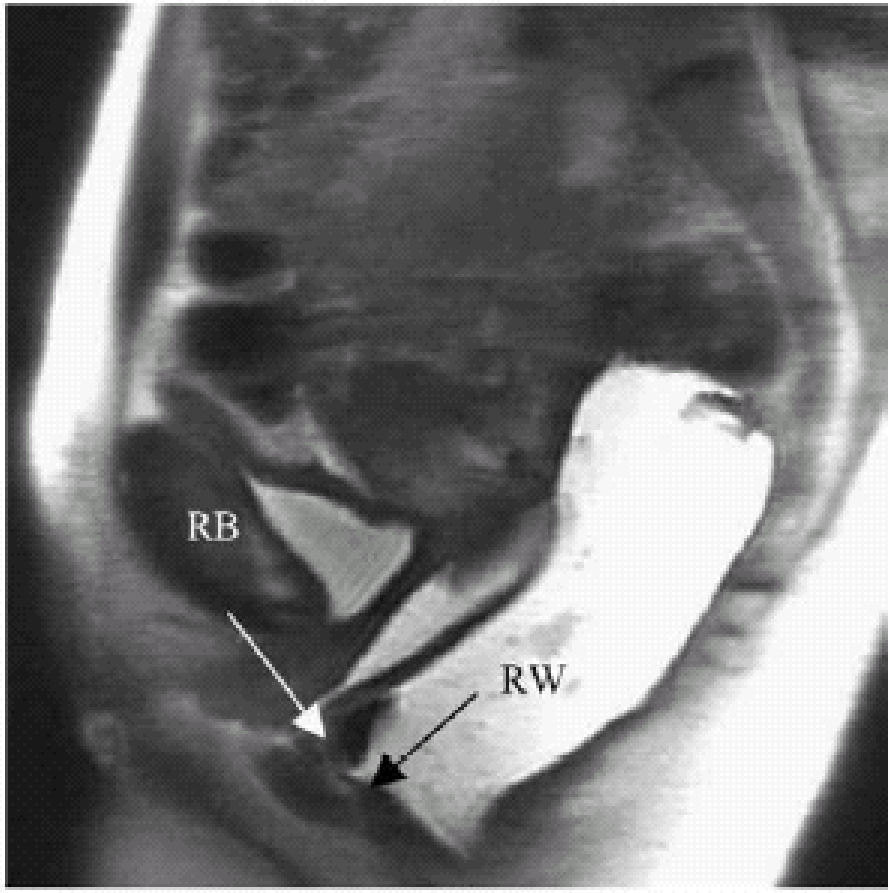

(d)

ELSEVIER

European Journal of Radiology 54 (2005) 276–283

EJR
EUROPEAN JOURNAL OF RADIOLOGY

www.elsevier.com/locate/ejrad

Triphasic MRI of pelvic organ descent: sources of measurement error

Geert L. Morren[a,*], Adrian G. Balasingam[b], J. Elisabeth Wells[c], Anne M. Hunter[b], Richard H. Coates[b], Richard E. Perry[a]

[a] *The Bowel and Digestion Centre, The Oxford Clinic, 38 Oxford Terrace, Christchurch, New Zealand*
[b] *Christchurch Radiology Group, P.O. Box 21107, 4th Floor, Leicester House, 291 Madras Street, Christchurch, New Zealand*
[c] *Department of Public Health and General Medicine, Christchurch School of Medicine, St. Elmo Courts, Christchurch, New Zealand*

Received 21 August 2003; received in revised form 6 May 2004; accepted 10 May 2004

Mean (S.D.) values and standard error of measurement (S.E.M.) of pelvic organ movement during straining as measured by triphasic dynamic MRI and factors affecting error of the measurements made

Anatomical reference point	Downward/ anterior movement[a]	Cystographic/ proctographic/ post-evacuation phase	Mean[b] (S.D.)	S.E.M. for one observation from one woman[c]	Significant sources of variation[d]	Primary recommendation to decrease error[e]
Bladder neck	D	C	12 (10)	9	S, O	Repeat measurements
Bladder neck	A	C	0 (8)	8	S, O	Repeat measurements
Bladder base	D	C	21 (15)	9	S, S*W	Repeat examination
Bladder base	A	C	−1 (6)	6	S, W, O	Repeat measurements
Introitus vaginae	D	P	−9 (19)	22	W, O, W*O	Calibrate observers
Introitus vaginae	A	P	24 (15)	16	W, O, W*O, S*W*O	Calibrate observers
Posterior fornix	D	P	28 (14)	8	S, S*W	Repeat measurements
Posterior fornix	A	P	0 (7)	6	S*W*O	Repeat measurements
Anterior rectal wall	D	P	53 (17)	10	S, S*W	Repeat measurements
Anterior rectal wall	A	P	7 (12)	11	O, S*W*O	Calibrate observers
Bulge of the anterior rectal wall	A	P	−16 (10)	5	S, S*W*O	Repeat measurements
Anorectal junction	D	P	33 (14)	10	S	Repeat measurements
Anorectal junction	A	P	−5 (10)	6	S, S*W	Repeat measurements, repeat examination[f]
Bladder neck	D	E	27 (11)	5	S, S*W, S*W*O	Repeat examination
Bladder neck	A	E	−3 (4)	4	S, W, O	Repeat measurements
Bladder base	D	E	32 (18)	9	S, S*W	Repeat examination
Bladder base	A	E	−8 (4)	4	S	Repeat measurements
Cul-de sac	D	E	24 (13)	9	S, S*W, O	Repeat examination, repeat measurements[f]
Cul-de sac	A	E	−6 (10)	11	S*W	Repeat examination, repeat measurements[f]
Vaginal axis	–	E	36.5 (23.9)	13.7	S, O, S*W*O	Calibrate observers.
Pouch of Douglas	D	E	20 (16)	9	S, S*W	Repeat examination
Pouch of Douglas	A	E	4 (9)	9	S*W	Repeat examination, repeat measurements

CLINICAL IMAGING

Dynamic MR Imaging of Outlet Obstruction

Nicolae Bolog, Dominik Weishaupt

Institute of Diagnostic Radiology, University Hospital, Zürich, Switzerland

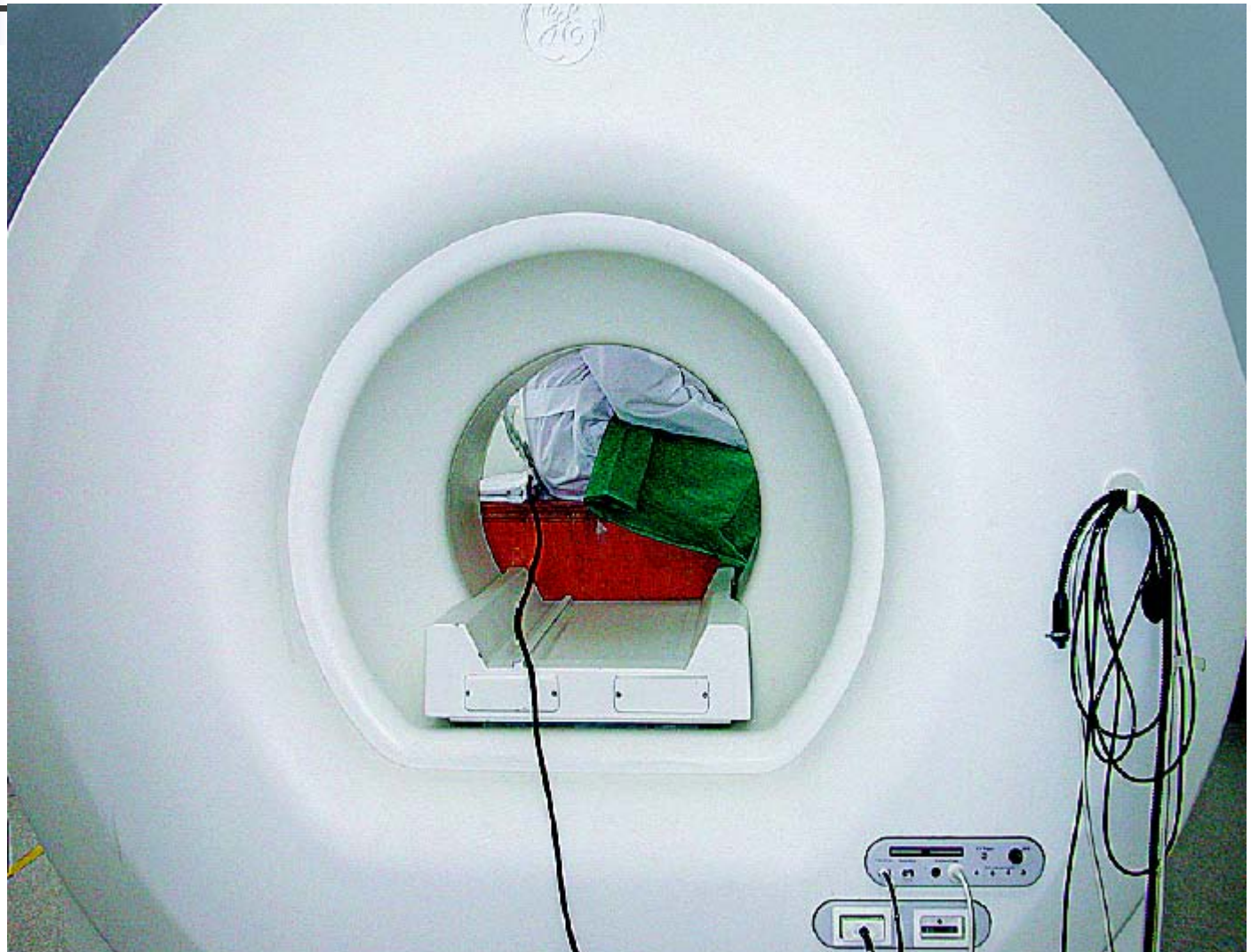

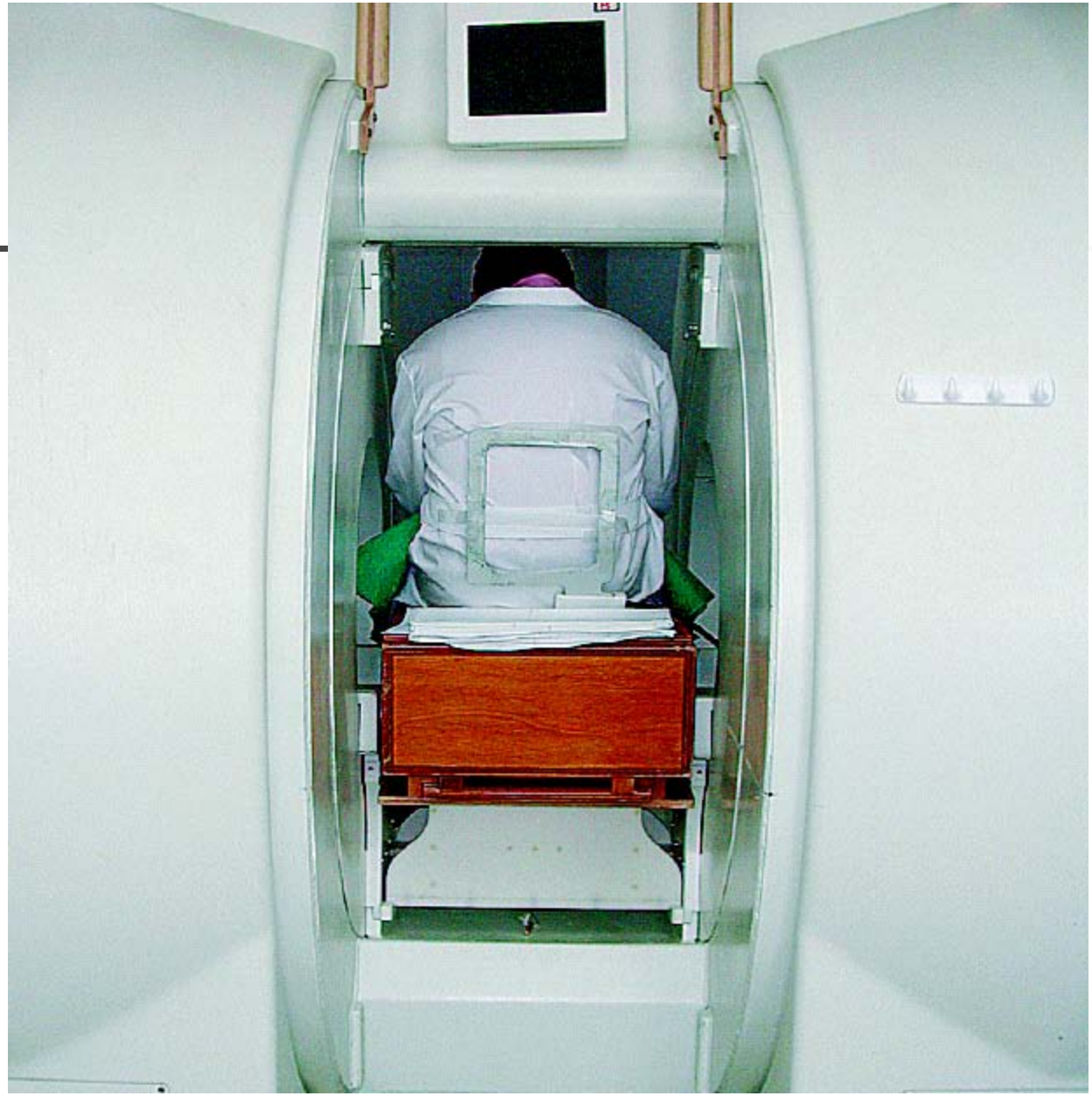

… 1 Quantifiant

- La réalisation d’une exploration précisant:
  - la topographie de la rectocèle
  - sa morphologie
  - sa cinétique d’évacuation

….n’est pas déraisonnable

Qu’attendre des examens?

- Quantifier objectivement le handicap
- Rechercher des associations fonctionnelles
- Identifier les éléments de moins bon pronostic
- Choisir les thérapeutiques les plus adaptées

Conservative management of pelvic organ prolapse in women (Review)

Hagen S, Stark D, Maher C, Adams E

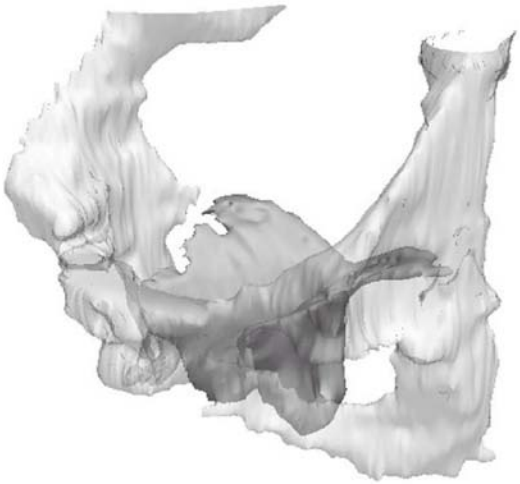

THE COCHRANE COLLABORATION®


Gastro fort
LIH 3
28.10
13

1


Gastro fort
LIH 3
28.10.0
13.2
/3

2

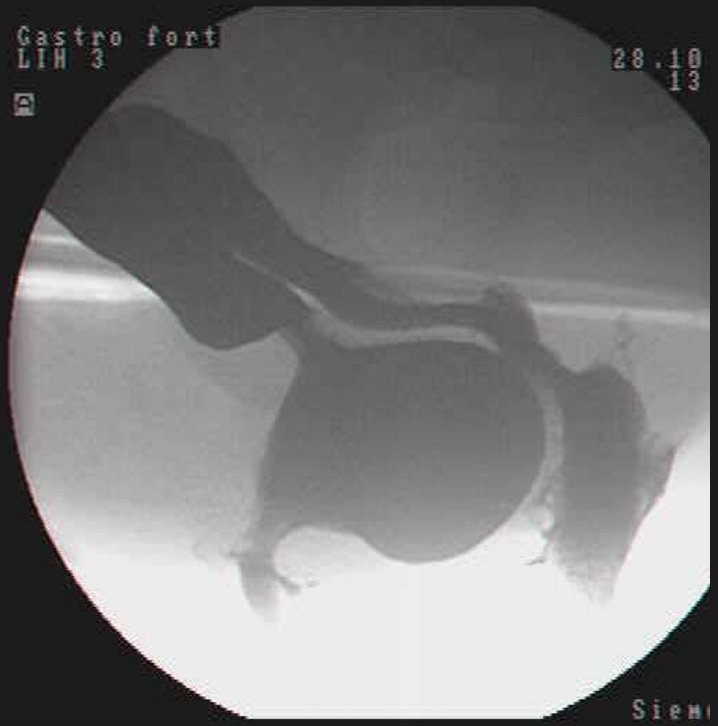
Gastro fort
LIH 3
28.10
13
Siem

3


Gastro fort
LIH 3
28.10.0
13.21
/3
Siemens

4

Anisme

N = 59 . Cure chirurgicale trans anale
suivi médian 19 mois

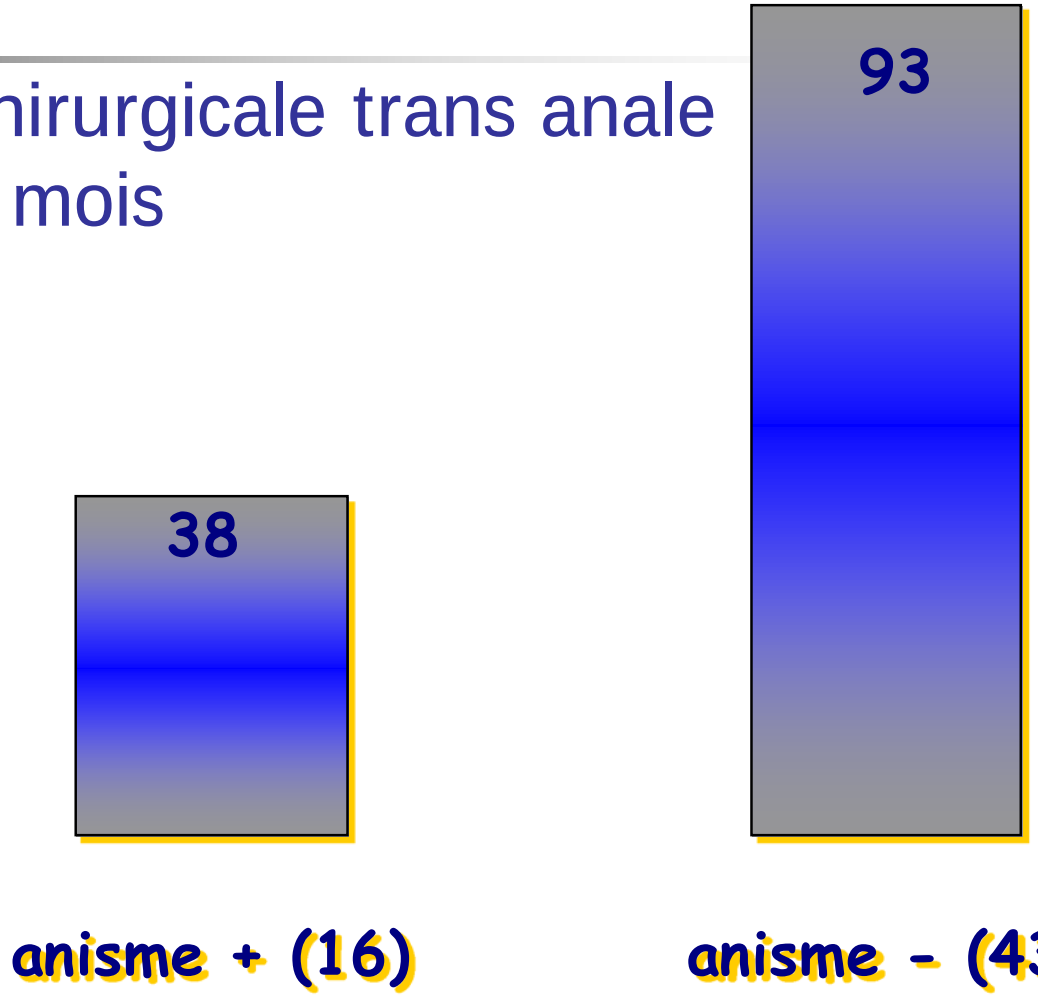

Tjandra et al Dis Colon Rectum 99

Botox 30 U. N = 14. 2 mois

Pressions de repos

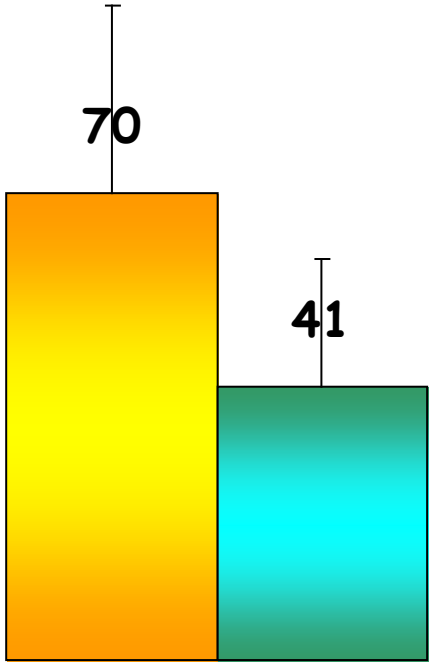

Profondeur de la rectocèle

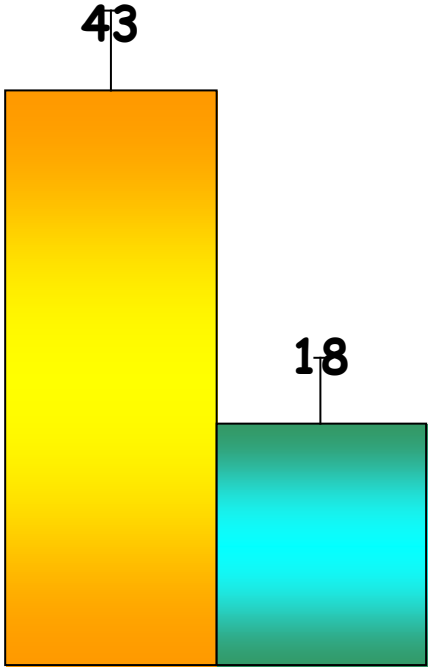

Maria et al Surgery 01

Biofeedback N = 25 (suivi médian 10 mois)

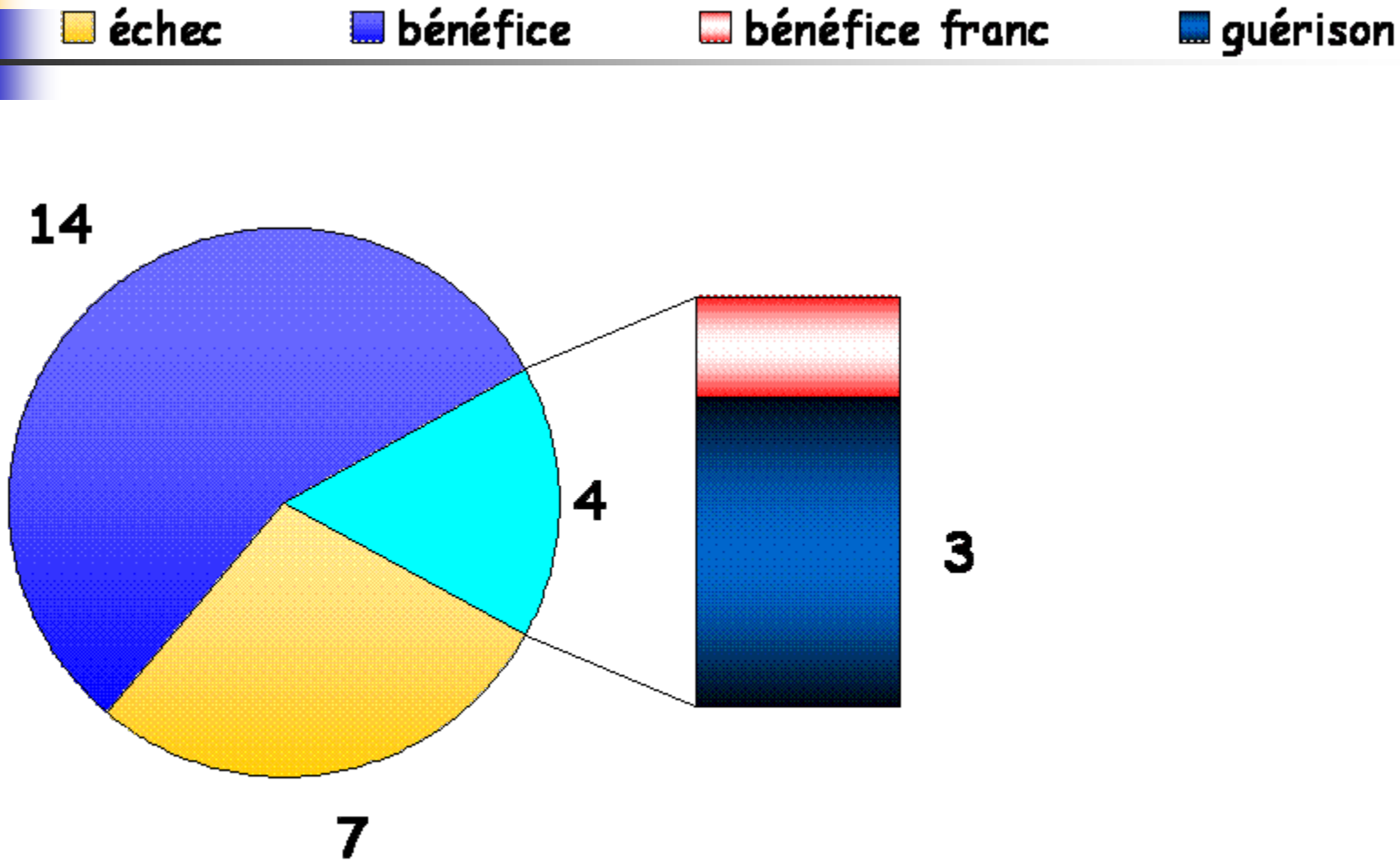

Mimura et al Dis Colon Rectum 2000

Comparison of Levator Ani Muscle Defects and Function in Women With and Without Pelvic Organ Prolapse

John O. L. DeLancey, MD, Daniel M. Morgan, MD, Dee E. Fenner, MD, Rohna Kearney, MD, Kenneth Guire, MS, Janis M. Miller, PhD, APRN, Hero Hussain, MD, Wolfgang Umek, MD, Yvonne Hsu, MD, and James A. Ashton-Miller, PhD

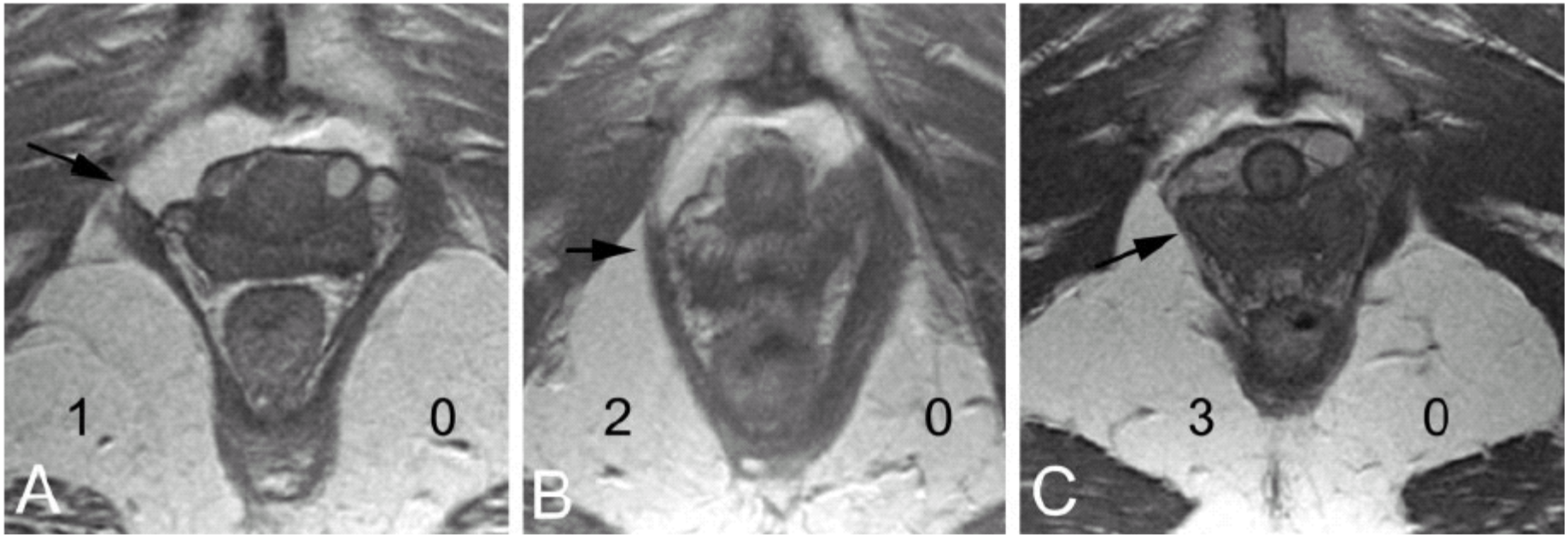

Quantification of Levator Ani Cross-Sectional Area Differences Between Women With and Those Without Prolapse

Yvonne Hsu, MD, Luyun Chen, MS, Markus Huebner, MD, James A. Ashton-Miller, PhD, and John O. L. DeLancey, MD

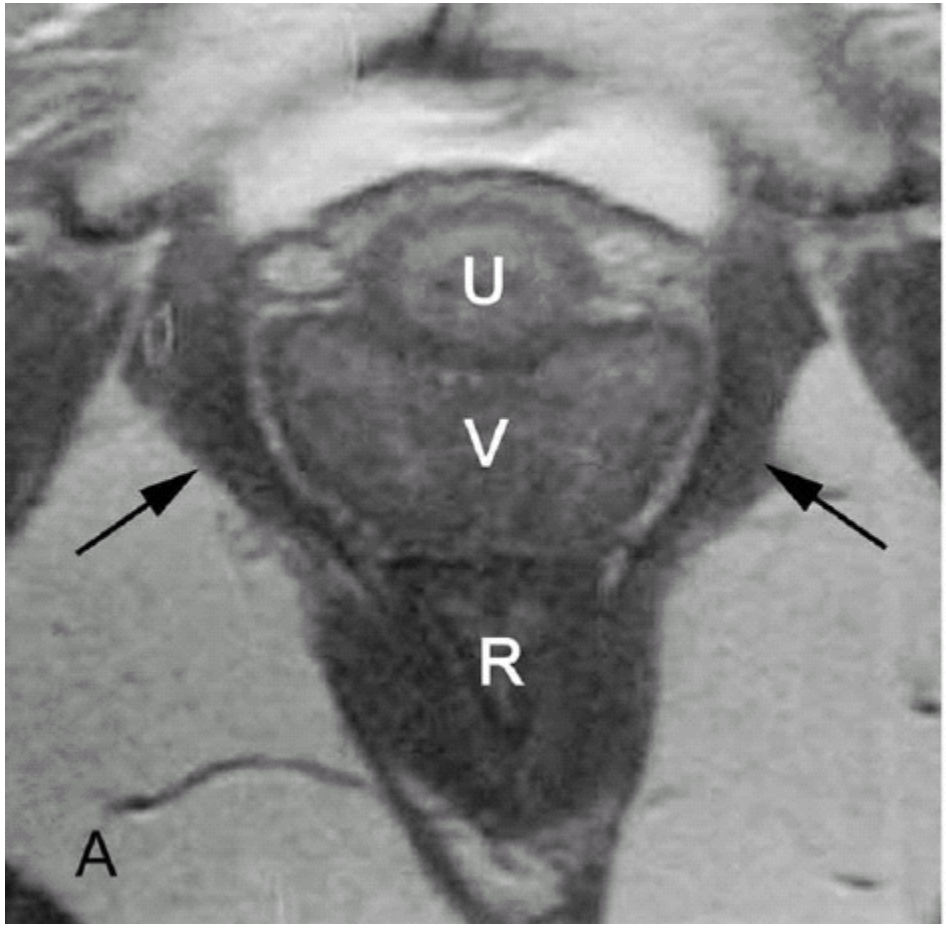

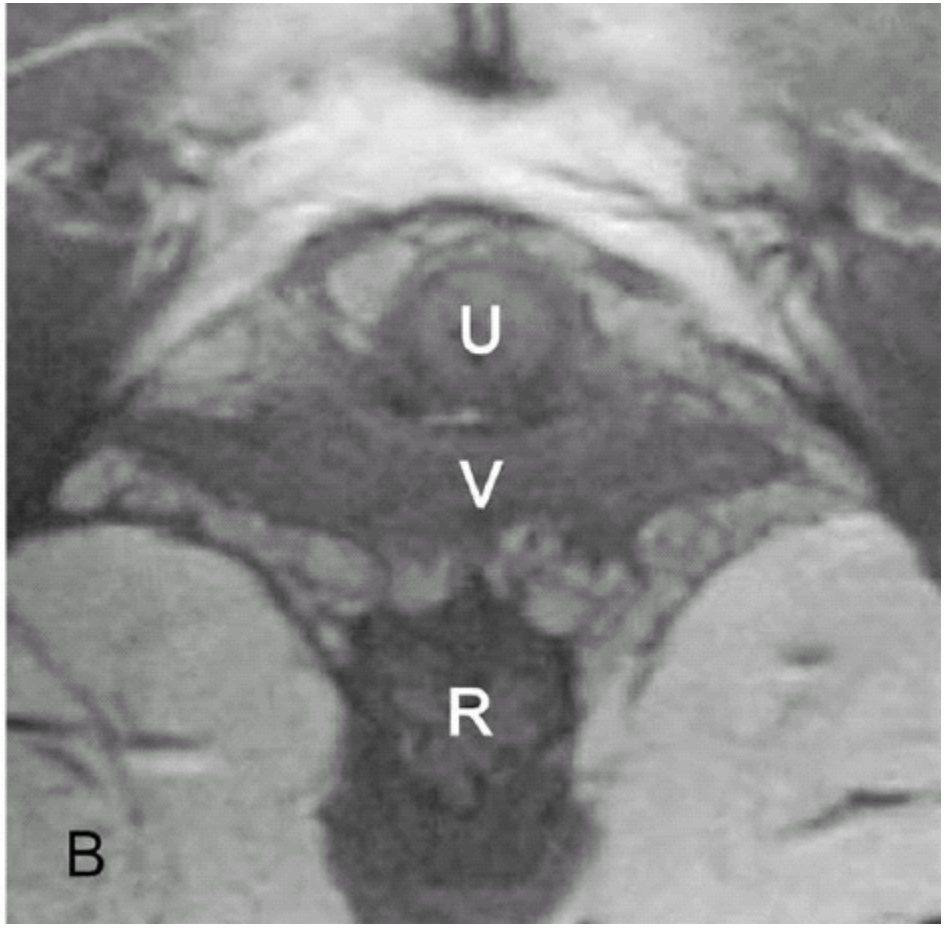

ELSEVIER

GRADING PELVIC PROLAPSE AND PELVIC FLOOR RELAXATION USING DYNAMIC MAGNETIC RESONANCE IMAGING

CRAIG V. COMITER, SANDIP P. VASAVADA, ZORAN L. BARBARIC, ANGELO E. GOUSSE, AND SHLOMO RAZ

ABSTRACT

Objectives. With significant vaginal prolapse, it is often difficult to differentiate among cystocele, enterocele, and high rectocele by physical examination alone. Our group has previously demonstrated the utility of magnetic resonance imaging (MRI) for evaluating pelvic prolapse. We describe a simple objective grading system for quantifying pelvic floor relaxation and prolapse.

Methods. One hundred sixty-four consecutive women presenting with pelvic pain (n = 39) or organ prolapse (n = 125) underwent dynamic MRI. The "H-line" (levator hiatus) measures the distance from the pubis to the posterior anal canal. The "M-line" (muscular pelvic floor relaxation) measures the descent of the levator plate from the pubococcygeal line. The "O" classification (organ prolapse) characterizes the degree of visceral prolapse beyond the H-line.

Results. The image acquisition time was 2.5 minutes per study. Each study cost $540. In the pain group, the H-line averaged 5.2 ± 1.1 cm versus 7.5 ± 1.5 cm in the prolapse group ($P < 0.001$). The M-line averaged 1.9 ± 1.2 cm in the pain group versus 4.1 ± 1.5 cm in the prolapse group ($P < 0.001$). Incidental pelvic pathologic features were commonly noted, including uterine fibroids, ovarian cysts, hydroureter, urethral diverticula, and foreign body.

Conclusions. The HMO classification provides a straightforward and reproducible method for staging and quantifying pelvic floor relaxation and visceral prolapse. Dynamic MRI requires no patient preparation and is ideal for the objective evaluation and follow-up of patients with pelvic prolapse and pelvic floor relaxation. MRI obviates the need for cystourethrography, pelvic ultrasound, or intravenous urography and has become the study of choice at our institution for evaluating the female pelvis. UROLOGY **54:** 454–457, 1999.

0022-5347/00/1645-1606/0
THE JOURNAL OF UROLOGY®

Vol. 164, 1606–1613, November 2000
Printed in U.S.A.

Female Urology

DYNAMIC HALF FOURIER ACQUISITION, SINGLE SHOT TURBO SPIN-ECHO MAGNETIC RESONANCE IMAGING FOR EVALUATING THE FEMALE PELVIS

ANGELO E. GOUSSE,*,† ZORAN L. BARBARIC, MICHAEL H. SAFIR, SHAHAR MADJAR,† ALAN K. MARUMOTO AND SHLOMO RAZ

From the Departments of Urology and Radiology, University of California-Los Angeles School of Medicine, Los Angeles, California

TABLE 3. *Comparative statistical parameters of MRI and physical examination in 45 of the 65 patients with pelvic prolapse who underwent surgical exploration and repair after physical examination*

	% Sensitivity		% Specificity		% Pos. Predictive Value		% Neg. Predictive Value	
	Physical Examination	MRI	Physical Examination	MRI	Physical Examination	MRI	Physical Examination	MRI
Urethrocele	100	100	83	75	93	94	100	100
Cystocele	97	100	100	83	100	97	86	100
Cuff prolapse	100	100	83	54	91	33	100	100
Uterine prolapse	87	83	100	100	100	100	25	20
Enterocele	73	87	83	80	84	91	71	83
Rectocele	97	76	50	50	94	96	66	10

BJOG: an International Journal of Obstetrics and Gynaecology
November 2005, Vol. 112, pp. 1547–1553

DOI: 10.1111/j.1471-0528.2005.00734.x

Prediction of findings at defecography in patients with genital prolapse

Jan-Paul W.R. Roovers,[a] Johanna G. van der Bom,[b] C. Huub van der Vaart,[a] A. Peter M. Heintz[a]

Table 1. Characteristics of all patients. Values are means [standard deviation] or numbers (percentage).

N	82	
Age (years)	56.4	[10.0]
No. of delivered children	2.6	[1.1]
Body Mass Index (kg/m^2)	25.2	[3.3]
No. with previous abdominal or pelvic surgery*	17	(21)
Cholecystectomy	5	
Appendectomy	7	
Caesarean section	5	
Adnex extirpation	1	
Anterior and/or posterior repair	4	
Burch colposuspension	1	
Defecation Distress Inventory		
Constipation	22	(27)
Feeling of incomplete evacuation	20	(24)
Incontinence for flatus	46	(56)
Incontinence for liquid or solid stools	14	(17)
Painful defecation	15	(18)
Difficulty emptying rectum	14	(17)
Urogenital Distress Inventory		
Frequency	53	(65)
Urgency	55	(67)
Types of urinary incontinence		
stress incontinence	45	(55)
urge incontinence	40	(49)
mixed incontinence	56	(35)
Difficulty emptying bladder	37	(45)
Findings at defecography		
Normal defecography	56	(68)
Abnormal defecography	26	(32)
enterocele	23	(28)
rectal intussusception	9	(11)
enterocele and rectal intussusception	6	(7)

Table 3. Univariable and multivariable analysis of the association of findings from patient history, pelvic examination and DDI and UDI questionnaire with the presence of rectocele or rectal intussusception at defecography.

	Univariate analysis		Multivariate analysis		
	OR	95% CI	β	OR	95% CI
Intercept			−3.02		
Medical history					
Age (per year)	0.97	0.93–1.02			
BMI (per kg/m^2)	1.04	0.90–1.20			
Parity (per child)	1.01	0.66–1.55			
History of abdominal or pelvic surgery	3.71	1.20–11.49	1.19	3.83	1.13–13.00
Pelvic examination					
Point C (per cm)	1.31	0.85–2.04			
Point Aa (per cm)	0.97	0.72–1.30			
Point Ap (per cm)	1.42	1.03–1.94	0.35	1.49	1.06–2.09
Defecation symptoms assessed by DDI					
Constipation	3.00	1.08–8.32	1.00	3.10	1.03–9.38
Feeling of incomplete evacuation	1.63	0.57–4.65			
Incontinence for flatus	0.88	0.34–2.23			
Incontinence for liquid and solid stools	0.84	0.24–2.97			
Painful defecation	1.57	0.49–4.99			
Difficulty emptying rectum	1.80	0.55–5.86			

… 2 la recherche

- d'un obstacle anal à la défécation est souhaitable
- de troubles autres de la statique pelvienne (considération ou traitement?):
  - Évaluation multidisciplinaire?
  - IRM?

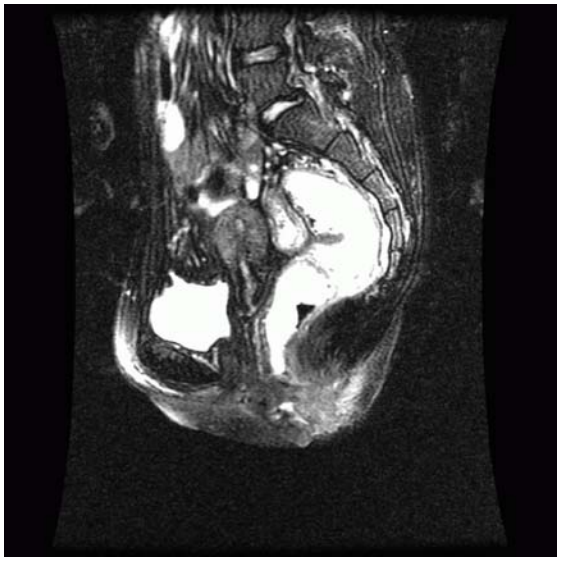

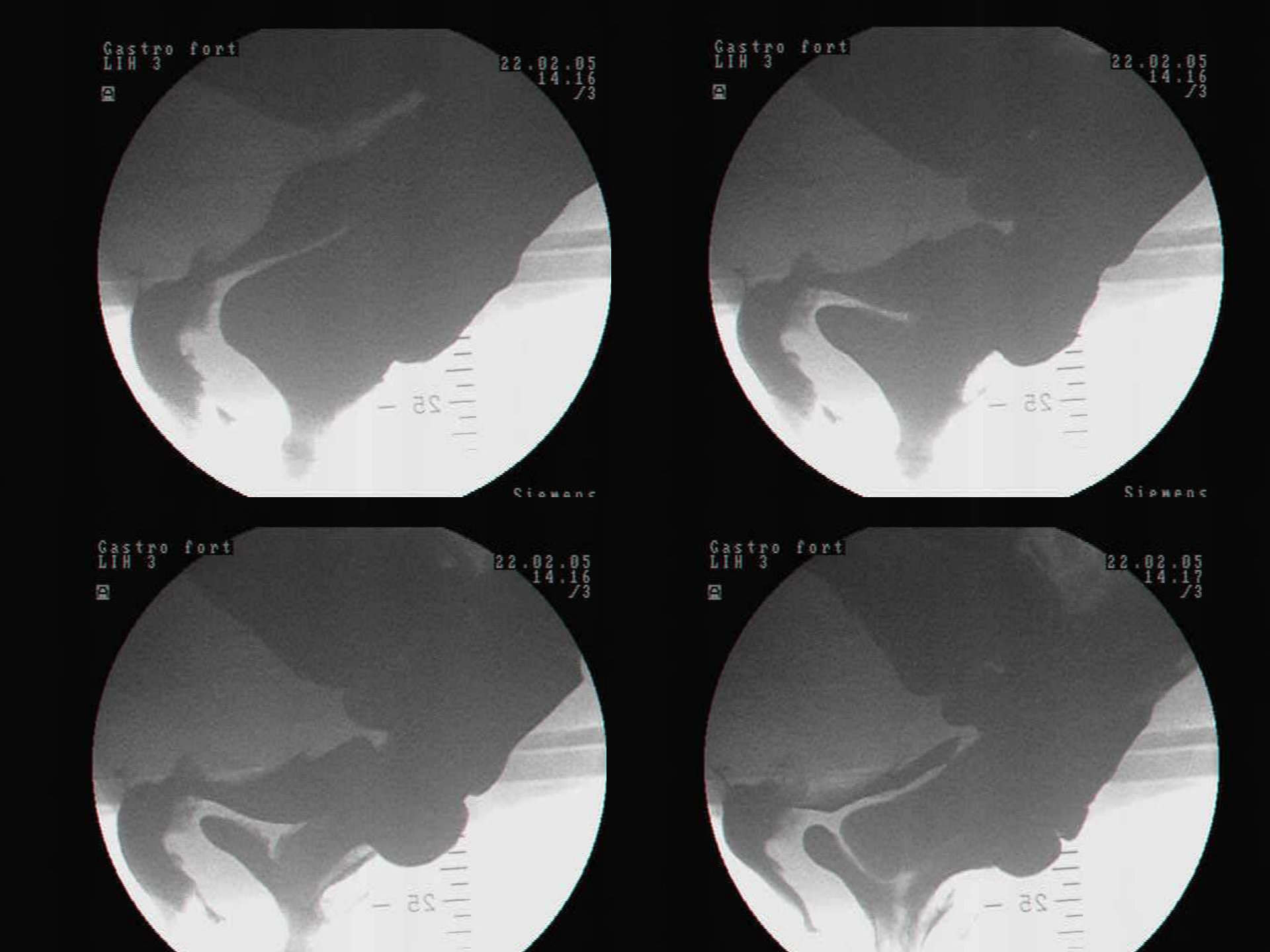
Gastro fort
LIH 3
22.02.05
14.16
/3
Gastro fort
LIH 3
22.02.05
14.16
/3
Gastro fort
LIH 3
22.02.05
14.16
/3
Gastro fort
LIH 3
22.02.05
14.17
/3

Qu’attendre des examens?

- Quantifier objectivement le handicap
- Rechercher des associations fonctionnelles ou lésionnelles
- Identifier les éléments de moins bon pronostic
- Choisir les thérapeutiques les plus adaptées

Analysis of Patients with Poor Outcome of Rectocele Repair

J. H. van Dam, Ph.D.,* W. C. J. Hop, Ph.D.,† W. R. Schouten, Ph.D.*

*From the Departments of *General Surgery and †Epidemiology and Biostatistics, University Hospital Dijkzigt, Rotterdam, the Netherlands*

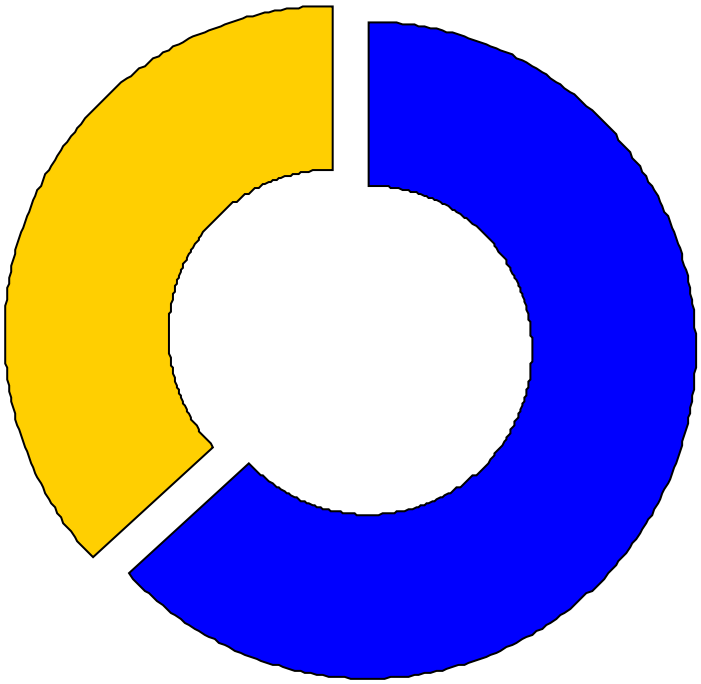

Symptômes	%
Constipation	16
Incontinence	08
Dyspareunie	41

Van Dam et al Dis Colon Rectum 00

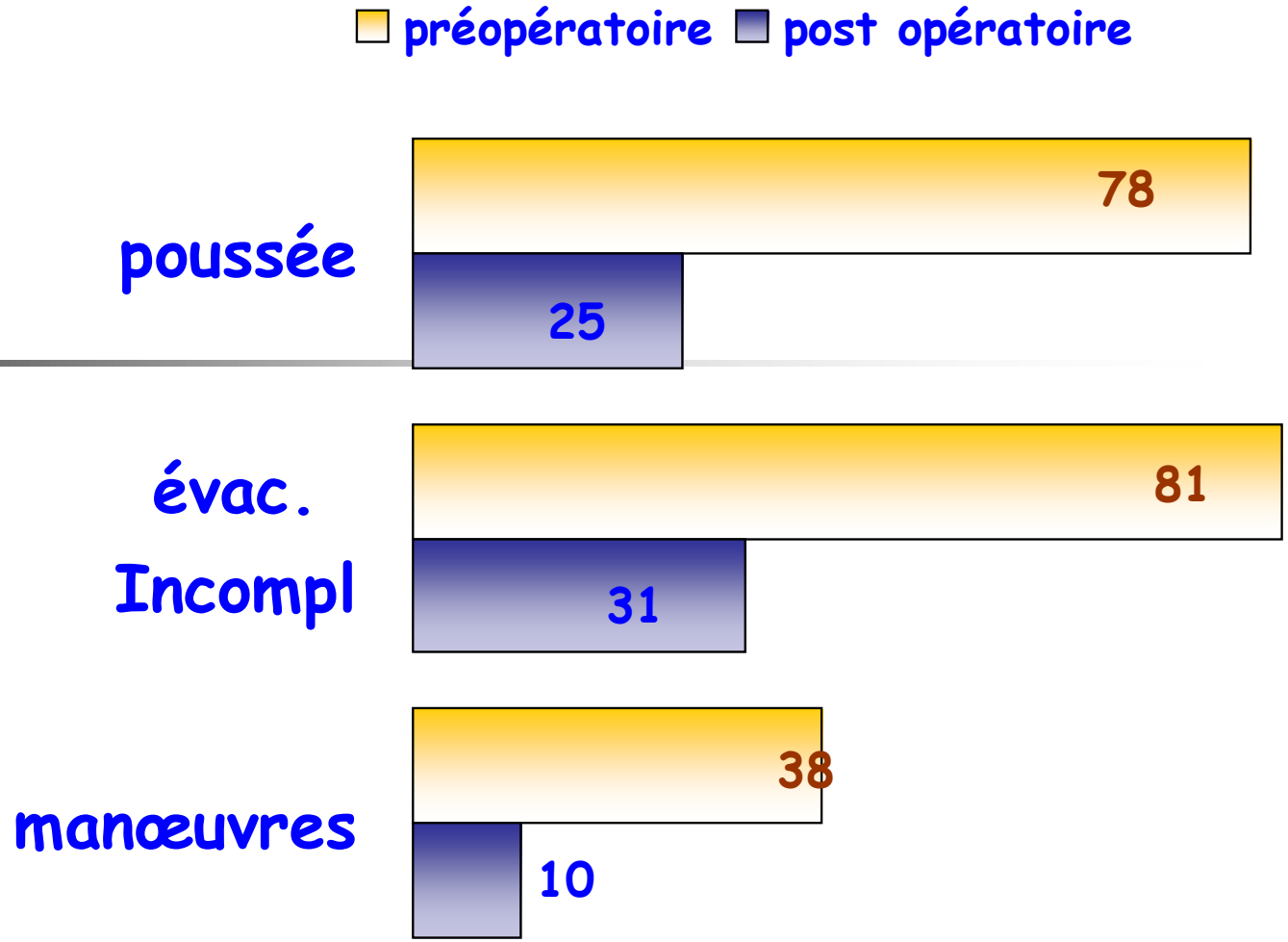

Diseases of the Colon & Rectum

Long-Term Results of the Anterior Delorme's Operation in the Management of Symptomatic Rectocele

S. M. Abbas, F.R.C.S., I. P. Bissett, F.R.A.C.S., M. E. Neill, F.R.A.C.S.,
A. K. Macmillan, M.B.C.h.B., D. Milne, F.R.A.C.R., B. R. Parry, F.R.A.C.S.

Colorectal Unit, University of Auckland, Auckland, New Zealand

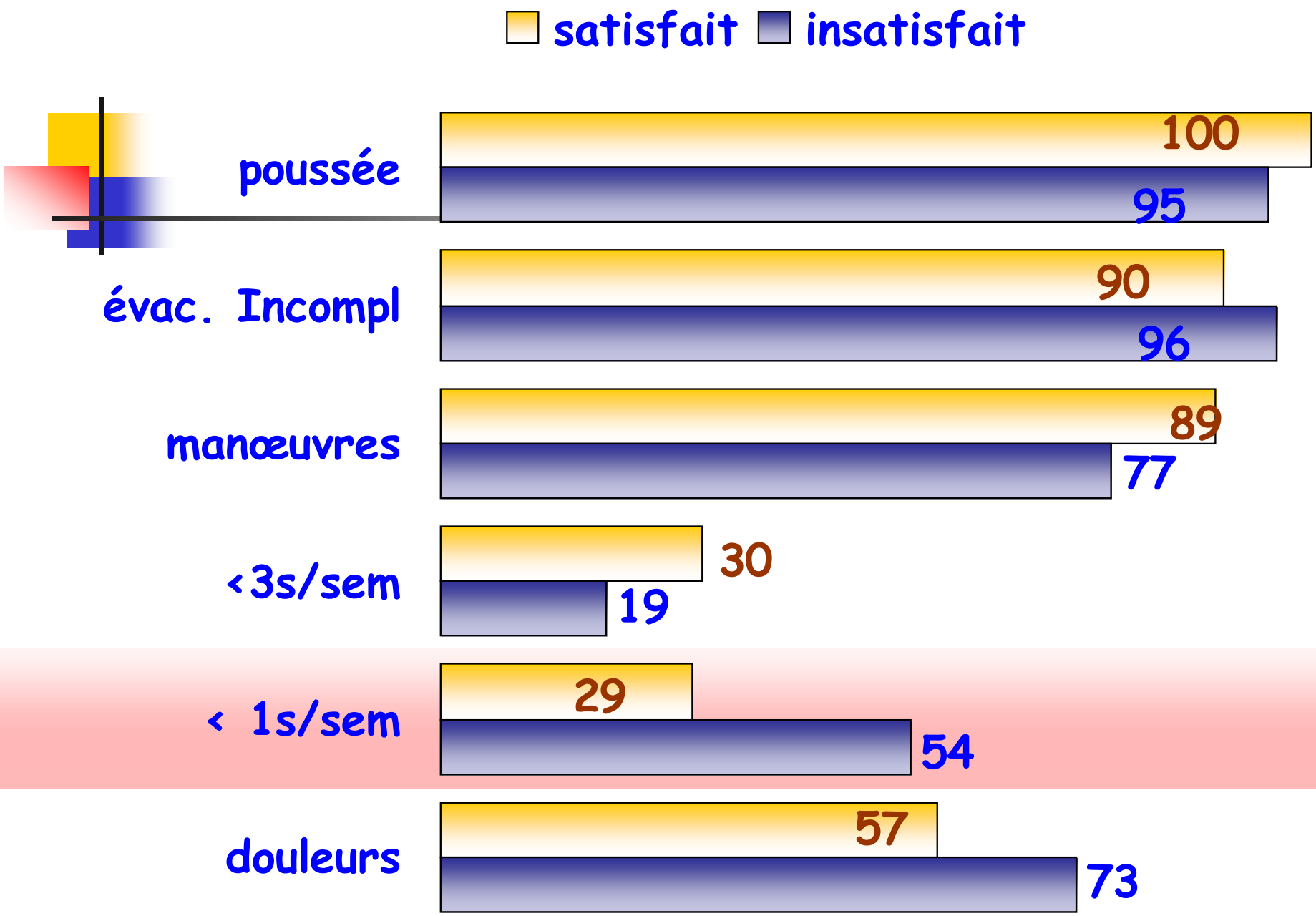
satisfait
insatisfait
poussée
100
95
évac. Incompl
90
96
manœuvres
89
77
<3s/sem
30
19
< 1s/sem
29
54
douleurs
57
73

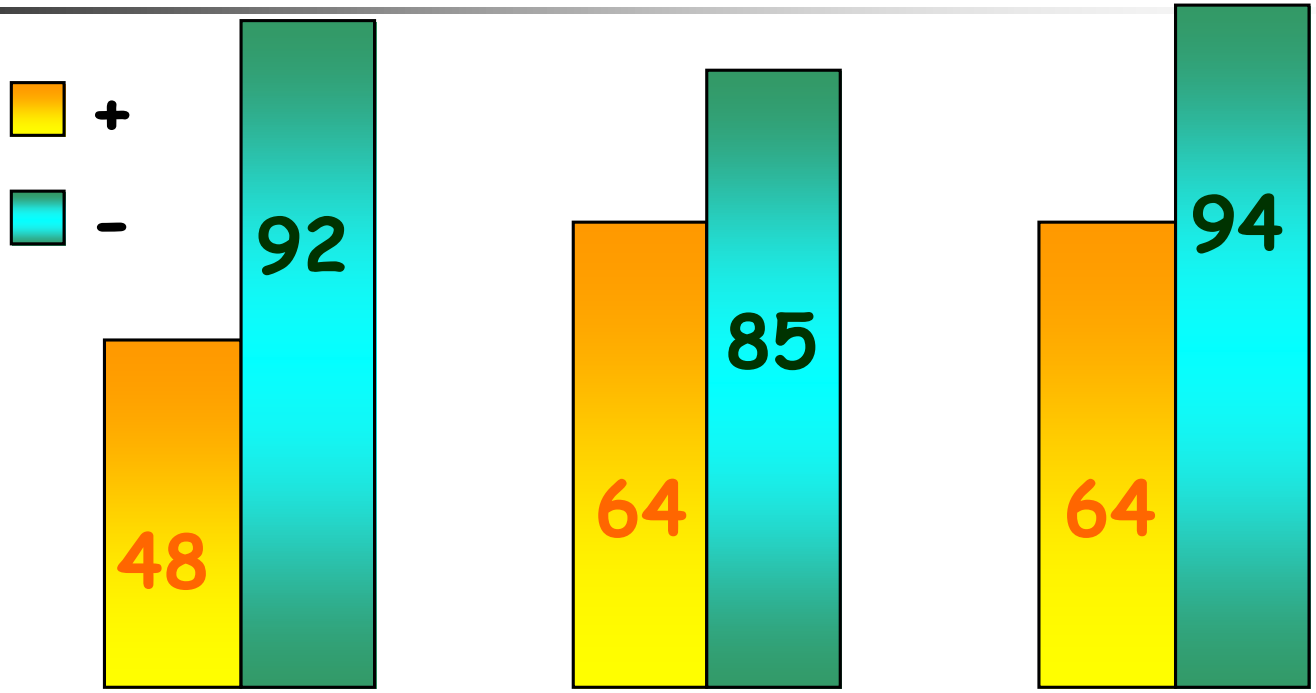

procidence hypotonie l'une ou l'autre

… 3

- Une exploration quantifiant:
  - l’hypotonie du canal anal
  - le degré de procidence rectale interne
  - la fréquence hebdomadaire des selles

est souhaitable parce que ces éléments conditionnent le résultat fonctionnel de la chirurgie.

Qu’attendre des examens?

- Quantifier objectivement le handicap
- Rechercher des associations fonctionnelles
- Identifier les éléments de moins bon pronostic
- Choisir les thérapeutiques les plus adaptées

Chirurgies....

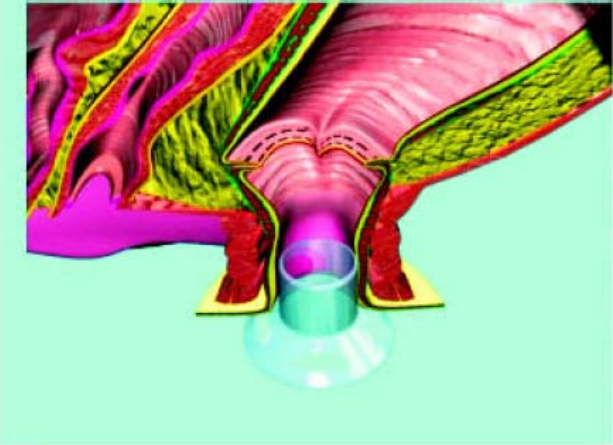

- Promontofixation
- Périnéorraphie postérieure
- Interposition prothétique
- Sullivan
- HémiDelorme antérieur, Delorme
- Rectoplastie périnéale
- Résection rectale trans anale
- ....

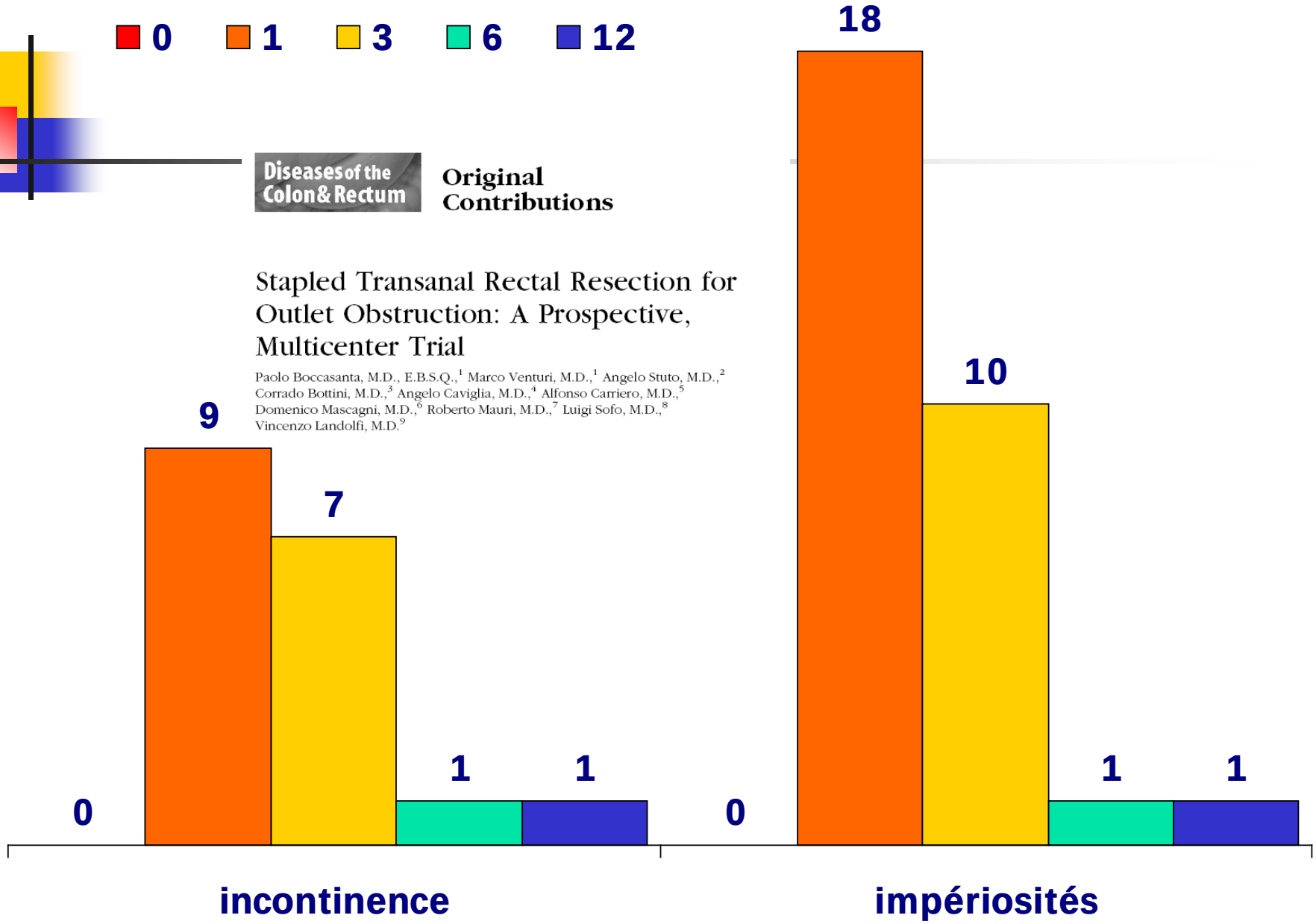
0
1
3
6
12
Diseases of the Colon & Rectum
Original Contributions
Stapled Transanal Rectal Resection for Outlet Obstruction: A Prospective, Multicenter Trial
Paolo Boccasanta, M.D., E.B.S.Q.,[1] Marco Venturi, M.D.,[1] Angelo Stuto, M.D.,[2] Corrado Bottini, M.D.,[3] Angelo Caviglia, M.D.,[4] Alfonso Carriero, M.D.,[5] Domenico Mascagni, M.D.,[6] Roberto Mauri, M.D.,[7] Luigi Sofo, M.D.,[8] Vincenzo Landolfi, M.D.[9]
0
9
7
1
1
0
18
10
1
1
incontinence
impériosités

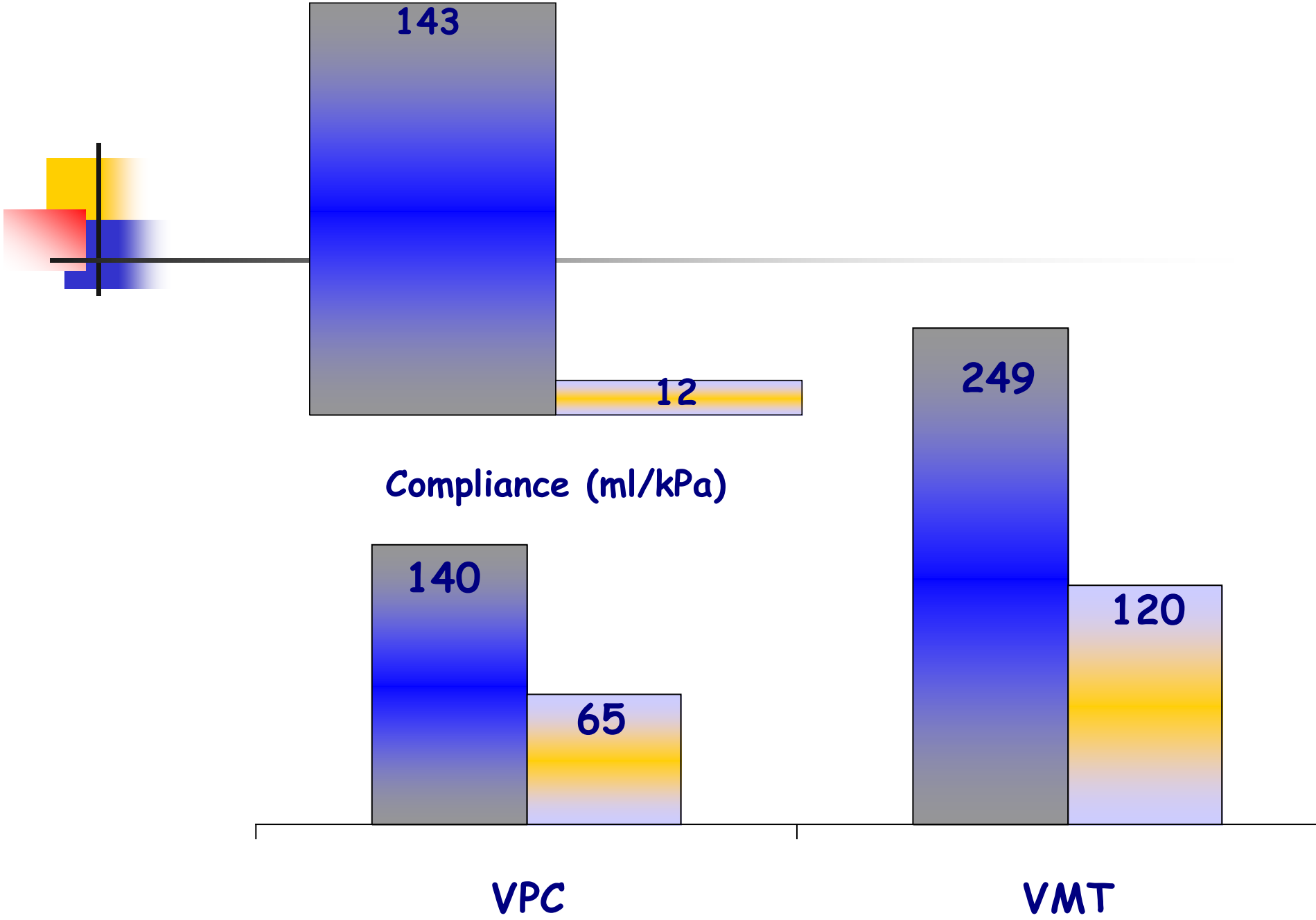

Plusa et al Br J Surg 95

Compliance rectale

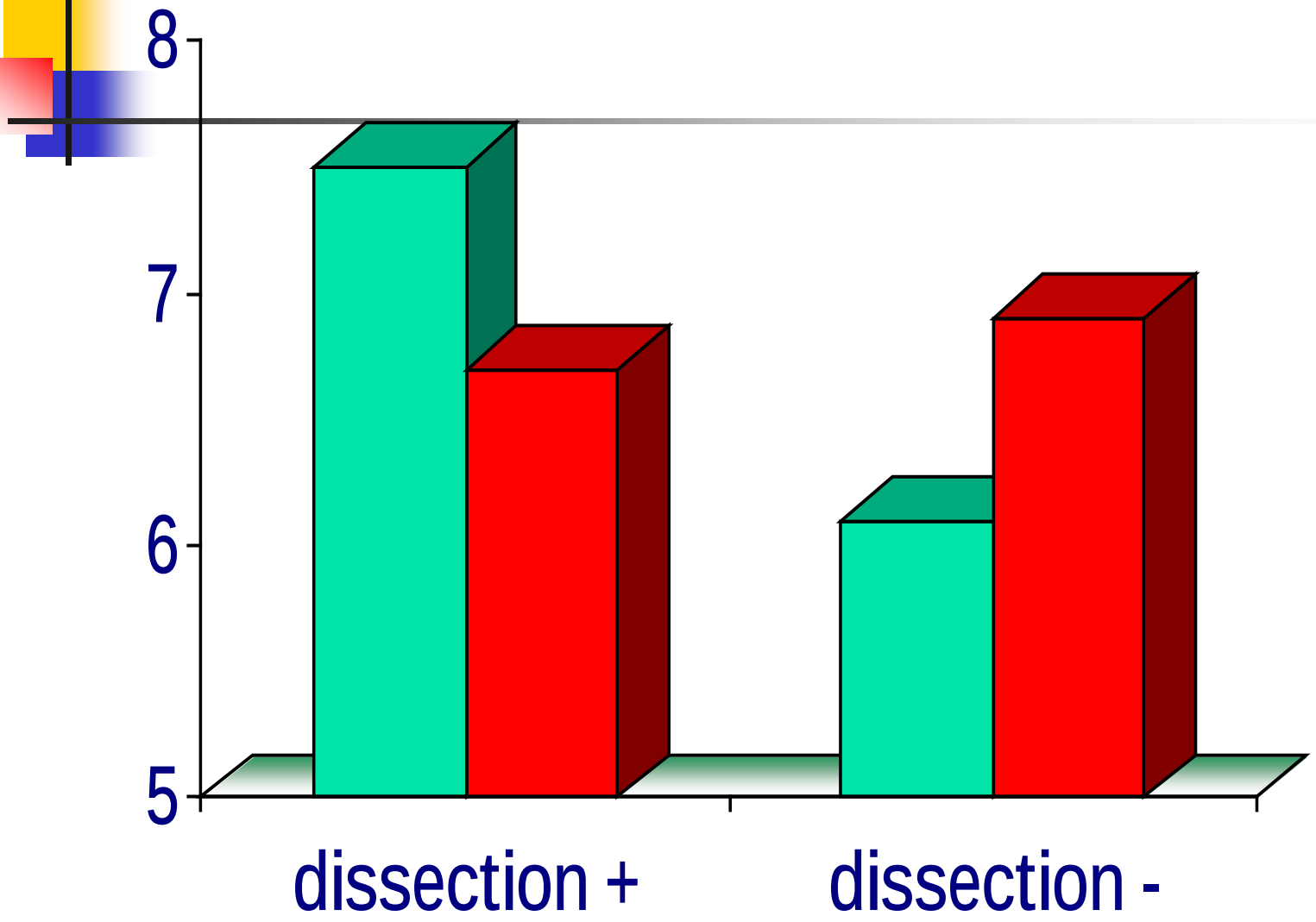

Mollen et al Dis Colon Rectum 00

Promontofixation

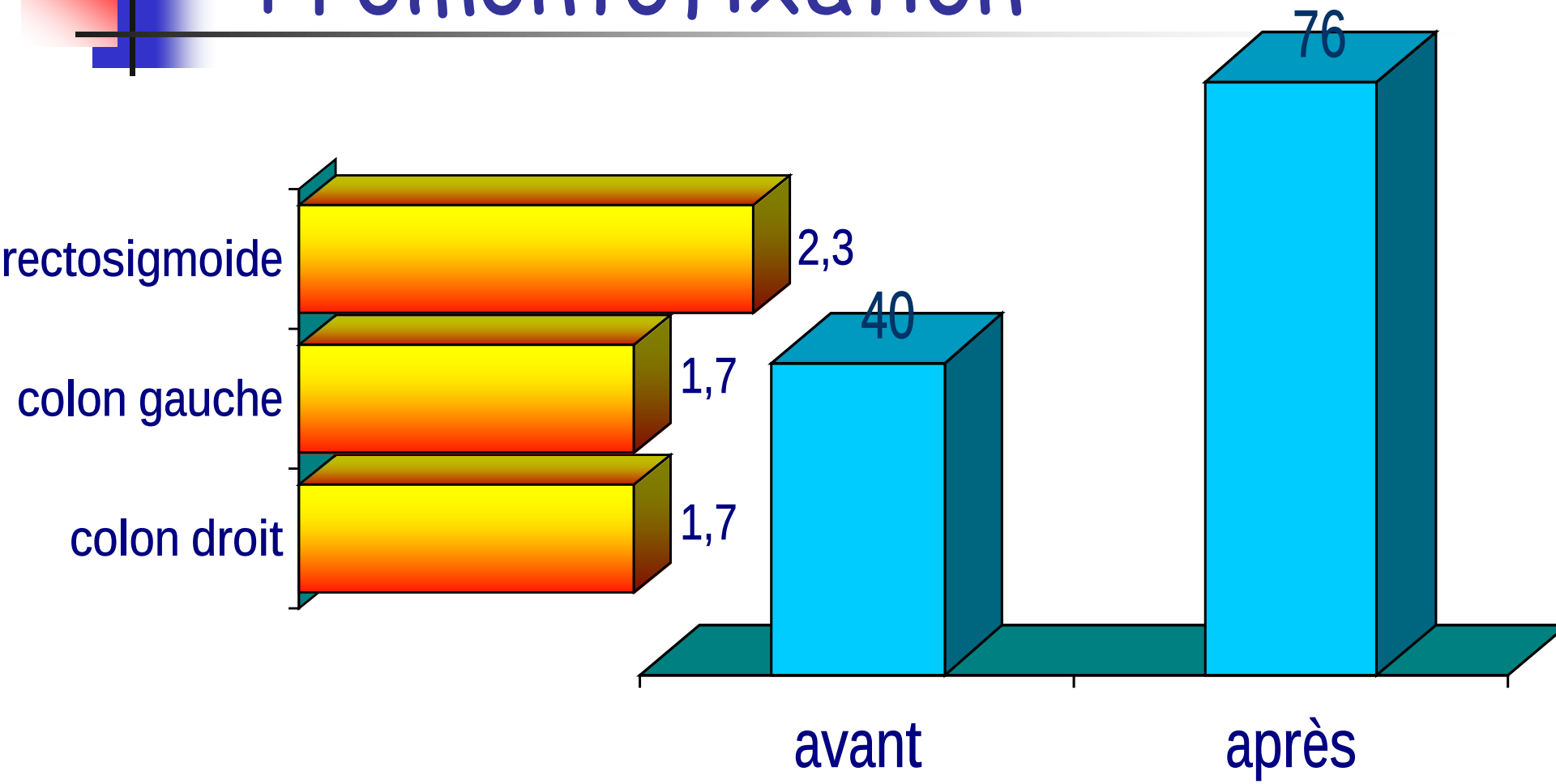

Mollen et al Dis Colon Rectum 00

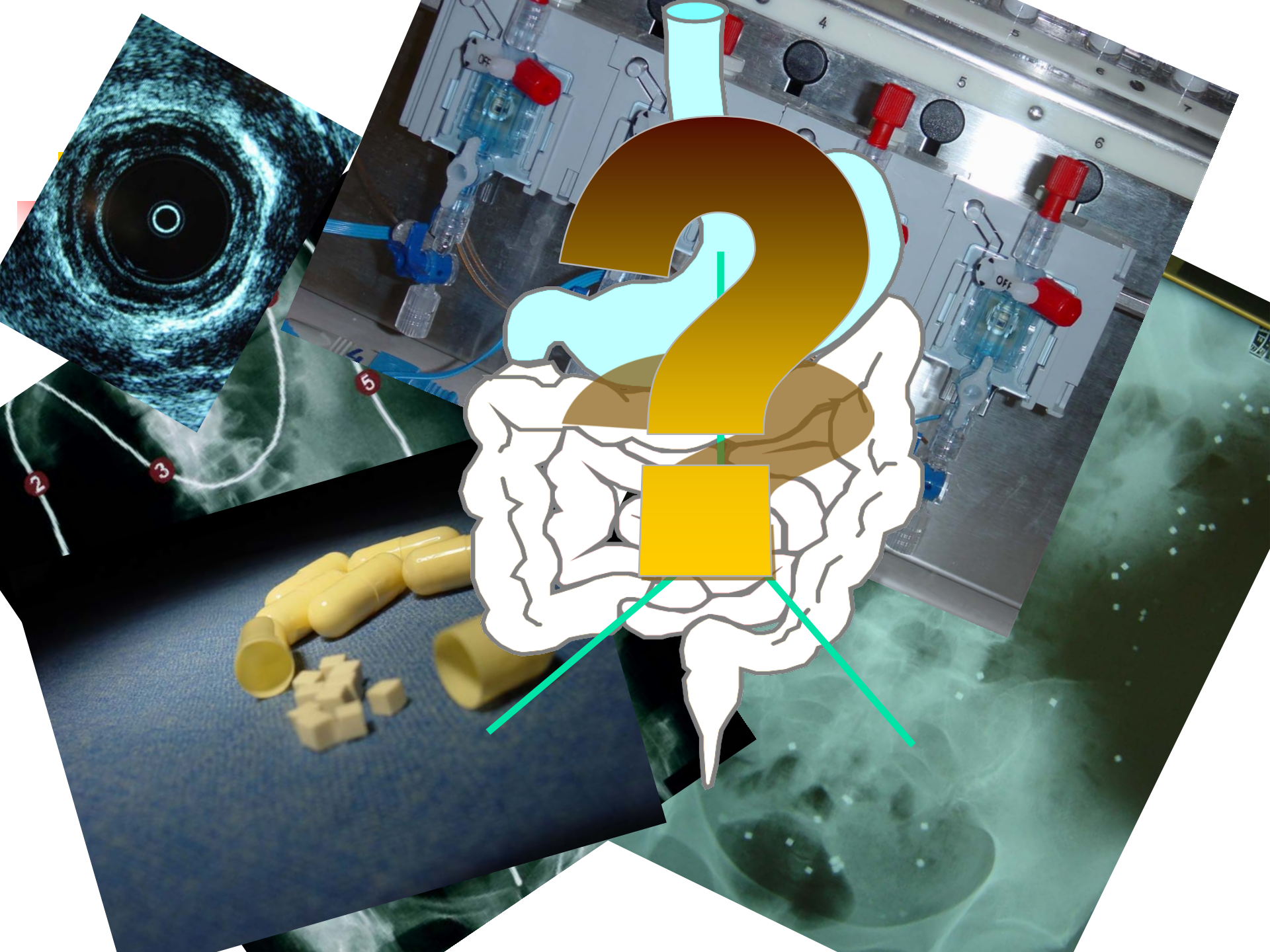

… 4 guider le traitement?

- Une exploration:
  - quantifiant les performances fonctionnelles anales et rectales (adaptation)
  - identifiant les troubles de la statique pelvienne associés
  - identifiant des troubles de la motricité colique

Peut être utile à la prise de décision thérapeutique

Impertinentes indications…

- Exploration radiologique dynamique
  - IRM dynamique
  - Echographie
  - Défécographie
- Exploration fonctionnelle anorectale
  - Manométrie anorectale avec compliance
- Étude fonctionnelle colique
  - Calendrier des selles
  - Temps de transit colique

- chirurgie trans anale
- chirurgie trans anale
- pexie abdominale
- chirurgie trans anale

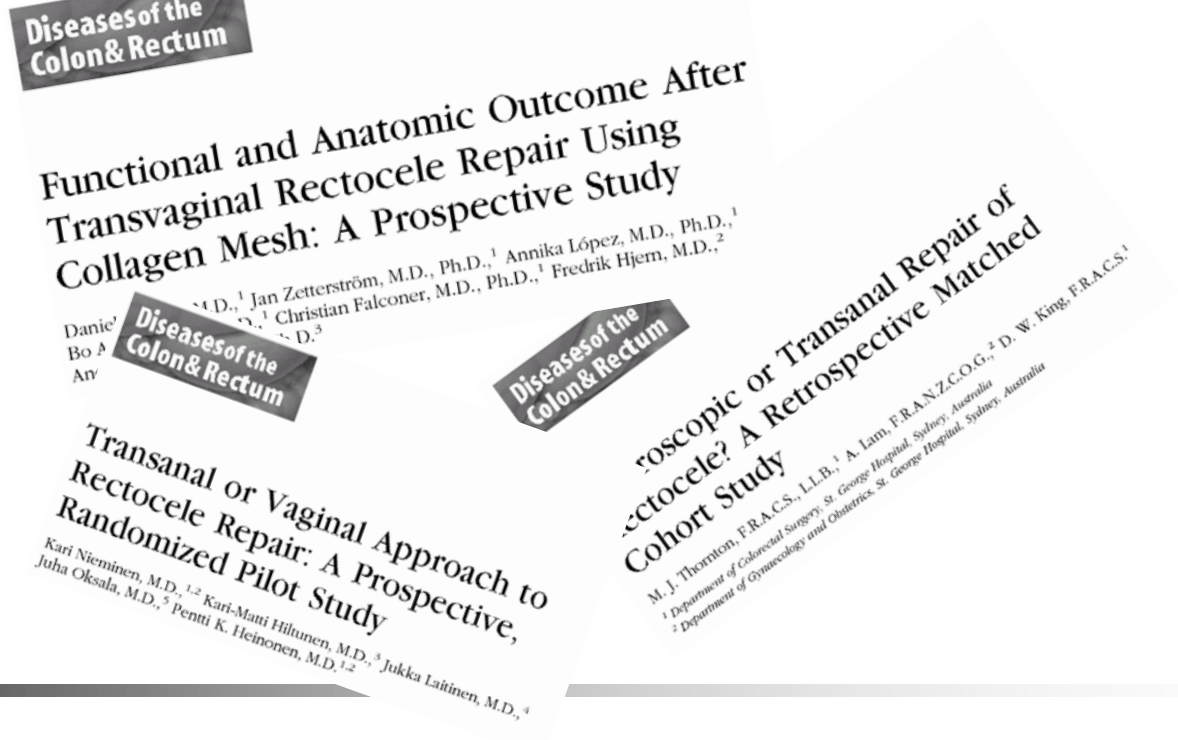

Impertinentes chirurgies.....

Calendrier des selles?

Trouble de la statique pelvienne Chirurgie basse planifiée

Incontinence

Pas d'incontinence

Explorations fonctionnelles anales
Explorations fonctionnelles rectales
Exploration pelvienne globale
Temps de transit colique

Exploration pelvienne globale
Temps de transit colique

Trouble de la statique pelvienne Chirurgie haute planifiée

constipation

Pas de constipation

Temps de transit colique?
Calendrier des selles?

?

techniques comparées	risque	OR	IC 95%
colpopexie abdominale vs sacrospinale	rechute anatomique	0.23	0.007-0.77
colpopexie abdominale vs sacrospinale	dyspareunie post opératoire	0.39	0.18-0.86
colpopexie abdominale vs sacrospinale	réintervention pour prolapsus	0.46	0.19-1.11
voie vaginale vs transanale des colpocèles postérieures	rechute (rectocèle et entérocèle)	0.24	0.09-0.64
plastie fasciale isolée ou associée au TVT	prévention IUE	5.5	1.36-22.32

Cochrane Database Syst Rev	Prolapsus vaginal	14 essais randomisés	1004 personnes traitées

Maher et al Surgical management of pelvic organ prolapse in women Cochrane Database Syst Rev 2004 18:CD004014

Faut il explorer?

Surgical management of pelvic organ prolapse in women (Review)

Maher C, Baessler K, Glazener CMA, Adams EJ, Hagen S

THE COCHRANE COLLABORATION®

FMC
HGE